



## Regular article

# Role of digital infrared thermal imaging in the diagnosis of breast mass: A pilot study

## Diagnosis of breast mass by thermography

Talha Sarigoz<sup>a,\*</sup>, Tamer Ertan<sup>b</sup>, Omer Topuz<sup>b</sup>, Yusuf Sevim<sup>c</sup>, Yasemin Cihan<sup>d</sup>

<sup>a</sup> Clinic of General Surgery, Sason State Hospital, Batman, Turkey

<sup>b</sup> Clinic of General Surgery, Kayseri Training and Research Hospital, Kayseri, Turkey

<sup>c</sup> Clinic of General Surgery, Ankara Numune Training and Research Hospital, Ankara, Turkey

<sup>d</sup> Clinic of Radiation Oncology, Kayseri Training and Research Hospital, Kayseri, Turkey

## ARTICLE INFO

## Keywords:

Thermography  
Breast cancer  
Fibroadenoma  
Temperature  
Granulomatous mastitis  
Ductal carcinoma

## ABSTRACT

**Background:** This paper summarizes the role of Digital Infrared Thermal Imaging (DITI) in the diagnosis of breast mass.

**Methods:** Of total, 54 patients with palpable breast mass were enrolled in the study. Using DITI, minimum, average and maximum temperature values of each lesion site and its counterpart were measured, differences were used as a measure of symmetry. 0.5 °C was selected as a reference cut-off. Subsequent to thermal imaging, all patients underwent US examination. Mammographic examination was performed upon clinician request. All lesions were core-biopsied. Results of thermal imaging according to the above-mentioned criteria was compared with histopathological results.

**Results:** Pathological evaluation revealed 21 invasive ductal carcinoma, 18 fibroadenoma, 9 cyst and 6 granulomatous mastitis. When mean temperature values were evaluated, fibroadenomas differed from malignant lesions significantly, whereas there was not statistically significant difference between granulomatous mastitis and invasive ductal carcinoma. Cysts were significantly different from malignant lesions only in terms of maximum temperature. It was shown that DITI can differentiate benign lesions from malignant with sensitivity up to 95.24% and specificity up to 72.73%.

**Conclusion(s):** This pilot study has shown that DITI can play a role in differentiating fibroadenoma and cyst from invasive ductal carcinoma in patients with palpable breast-mass. Since fibroadenomas are mostly seen in younger women, emergence of thermal symmetry analysis as an adjunct method in symptomatic patients with dense breasts seems most promising and important.

## 1. Introduction

Breast-mass complaints were the most common cause of referral (89.91%) for breast cancer patients to surgery clinics in Turkey [1]. Opportunistic screening made only 4% of referrals in these patients. These results can be attributed to low breast health awareness, difficulty accessing to screening services and socio-cultural factors. This situation might be improved with a screening tool reaching communities rather than waiting for symptoms to get screened.

Today, mammographic screening is still the only option for early breast cancer detection [2]. Breast ultrasound (US) is used mostly as an adjunct method in case of focal abnormality on a previous mammogram [3]. But, those methods have limitations. For instance, radiation

exposure, reduced sensitivity in dense breasts and low specificity yielding too many biopsies are disadvantages of mammography (MMG) [4,5]. Breast ultrasound is operator dependent and magnetic resonance imaging (MRI) -which is recommended for specific group of patients- costs too much. Also, they require technical expertise and manpower. Furthermore, access to breast cancer screening is limited in many suburban and rural areas of Turkey due to lack of units [6].

Initial examples of medical thermal imaging had been introduced in the middle of last century but due to lack of technical capability and analysis tools, it was abandoned [7]. Primary origin point for thermal imaging is that human body is homoiothermic and body temperature changes are useful indicator of health status [8]. With the development of better sensors and analysis tools, thermography resurges in medical

\* Corresponding author at: Asagi Mahalle, Eski Tekel Caddesi, Sason Devlet Hastanesi, 72500 Batman, Turkey.  
E-mail address: [sarigozt.md@gmail.com](mailto:sarigozt.md@gmail.com) (T. Sarigoz).

imaging. It adds critical information to the best possible evaluation of breast. It confers advantages over conventional techniques for being portable, non-invasive, easily conducted, repeatable, and inexpensive. Moreover, contrast agent isn't required.

Considering advantages of DITI and socio-economic status of the Turkish population, infrared thermography can be a useful investigation where the clinical diagnosis is in doubt and the conventional methods are far from reach. In this regard, this pilot study was conducted to determine potential of DITI as an adjunct tool in diagnosis of breast masses in Turkish scenario.

## 2. Patients and methods

### 2.1. Study design and ethical aspects

This prospective, single-center, double-blinded diagnostic accuracy study was performed between May and September 2016 at Kayseri Training and Research Hospital with Erciyes University School of Medicine Research Ethics Committee approval under protocol number 2016/111. For this purpose, thermographic and radiological examiners were blinded to clinical breast exam and to each other.

### 2.2. Eligibility criteria

A total of 160 patients with breast complaints were referred to Kayseri Training and Research Hospital Department of General Surgery during 5 months period. The inclusion criteria for the participants were as follows: female patients aged between 18 and 70 years old and diagnosed with single breast lump on clinical examination. The exclusion criteria were as follows: patients with history of previous breast surgery or treatment, family history of breast cancer, presence of acute infection or chronic systemic diseases such as diabetes or vascular diseases, having bra cup size bigger than DD, obese patients (Body Mass Index > 30), use of non-steroid anti-inflammatory/steroid drugs or any other medication concurrently that could systemically or locally affect skin temperature (Fig. 1).

### 2.3. Thermal imaging procedure

Subsequent to clinical breast exam, the clinicians marked the lesion of concern and filled a thermography request sheet containing location of each lesion for reference of both the interpreting surgeon and

radiologists. All patients were told to refrain from exercise, smoking and alcohol at least a day before the imaging procedure. Thermal images were taken at the time of admission for post-menopausal patients. For pre-menopausal patients, 5th to 12th days or 21th day of menstrual cycle was preferred for least engorgement [9]. Exclusion criteria was determined according to the review by Cuevas and colleagues about factors influencing the use of thermography [10].

For digital infrared thermal imaging procedure, FLIR ThermaCam E45 (FLIR Systems Inc., Wilsonville, Oregon, USA) was used. This infrared camera detects signals over the spectral range of 7.5–13  $\mu\text{m}$  and have an image resolution of 320  $\times$  240 pixels. Its operating temperature range is from  $-20^\circ\text{C}$  to  $+250^\circ\text{C}$  with temperature resolution 0.1  $^\circ\text{C}$  at 25  $^\circ\text{C}$ .

Thermal images were taken in a room which was kept at constant 22–25  $^\circ\text{C}$  with humidity 50%  $\pm$  15%. The room and the patients weren't exposed to direct sunlight or air-flow. In order to avoid bias, the surgeon who took and interpreted thermal images was unaware of the patients' complaints, examination findings and imaging results such as detailed ultrasonography and mammography.

The operation and the device to be used were told to the patients and after taking patient consent, they were asked to remove their clothes and raise their hands above the head. After 15 min of rest to let the patients get used to room temperature, each breast was visualized at a distance of 2 m and then a total of 2 steady-state images from two directions including coronal plane view of mass and mirror-image site were taken. Thermal imaging process took approximately 10 s.

All images were analyzed using FLIR Quick Report 1.2 software program (FLIR Systems, Inc., North Billerica, MA, USA). Analysis can be made easily using this program either in numerical or graphical forms. For each lesion, 3 types of analysis were performed. Using "field" analysis tool, minimum, average and maximum temperature values of lesion site and mirror image site were measured and differences ( $\Delta T_1$ ,  $\Delta T_2$ ,  $\Delta T_3$ , respectively) were used as a measure of thermal symmetry. Thermograms exceeding 0.5  $^\circ\text{C}$  difference were categorized as asymmetric and abnormal.

Subsequent to thermal imaging, all patients underwent US examination. Radiologists measured the lesion size in the breast US in which the lesion manifested its greatest dimension. For patients aged above 40 years, mammographic examination was performed upon clinician request. After clinical and radiological examination, suspicious lesions were biopsied (ultrasound guided core needle biopsy). Results of thermal imaging according to the above-mentioned criteria was compared with histopathological results.

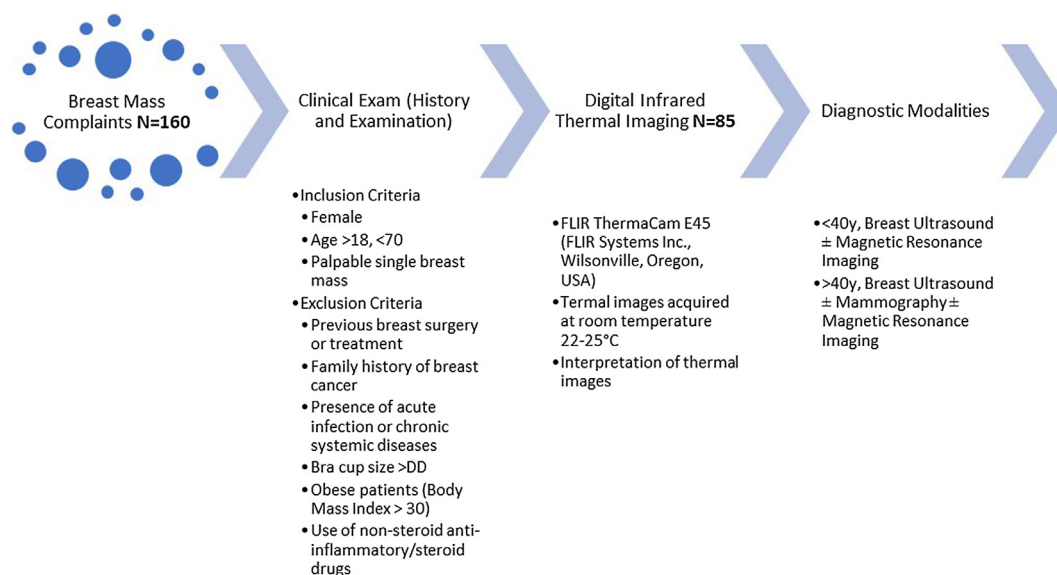


Fig. 1. The flowchart showing experimental process.

#### 2.4. Statistical analysis

Statistical analysis was performed using SPSS software (SPSS version 20.0, SPSS Inc., Chicago, IL, USA). All measured data were checked for normal distribution. The Mann-Whitney *U* test was used for the comparison of non-parametric data. The Chi-square statistic was used for the comparison of nominal variables. Temperature values were expressed in degrees Celsius (°C) and One-way ANOVA with Games-Howell Post Hoc Test was used for pairwise comparison. Finally, ROC was applied to evaluate accuracy, sensitivity, specificity, positive and negative predictive value for the DITI. P value less than 0.05 was accepted as statistically significant.

### 3. Results

Of total, 54 patients who were scheduled for tissue sample due to suspicious findings following clinical and radiological evaluation were recruited for this study. All of the subjects were symptomatic females and had single breast lump on clinical breast exam. The mean age was  $43.2 \pm 11$  (range, 20–66) years. Thirty-three (61%) patients were premenopausal and 21 (39%) patients were post-menopausal at the time of admission. The median ultrasound size of the malignant lesions was 20 mm (range, 9–60 mm) and for the benign lesions it was 18 mm (range, 9–67 mm) at a non-significant difference ( $p > 0.05$ ). Of the 54 patients, 21 (38.9%) of them were malignant (invasive ductal carcinoma), 18 (33.3) was fibroadenoma, 9 (16.7) was cyst and 6 (11.1) was granulomatous mastitis (GM) on core-biopsy. The clinicopathological characteristics of the patients were shown in Table 1 (Fig. 2A–D).

Table 2 shows the minimum, average and maximum mean temperature values of each pathological type. Granulomatous mastitis had the highest mean temperatures. The mean temperatures of invasive ductal carcinoma differed significantly from fibroadenoma. Between invasive ductal carcinoma and granulomatous mastitis, there was not significant difference. Regarding maximum temperature values, significant difference was observed between malignant lesions and cysts. Despite being insignificant, measured mean minimum and average temperature values of cysts were also considerably lower than malignant lesions (Table 2).

Following 3 types of analysis, temperature differences were calculated across sites and were expressed as the mean  $\pm$  standard deviation of the difference in the Table 3. Variables of malignant lesions were relatively higher than benign lesions at a high significant difference ( $p < 0.001$ ). When post-hoc subgroup analysis was performed, malignant lesions and granulomatous mastitis were not different regarding

**Table 1**  
The clinicopathological characteristics of the patients (n = 54).

	Malignant (n = 21)	Benign (n = 33)	P value
Age, y, mean $\pm$ SD	49.2 $\pm$ 9.6	39.3 $\pm$ 10.4	< 0.01
Menopausal status, n (%)			< 0.1
Pre-	9 (42.9)	24 (72.7)	
Post-	12 (57.1)	9 (27.3)	
Lesion localization, n (%)			NS*
Right breast	12 (57.1)	18 (54.5)	
Left breast	9 (42.9)	15 (45.5)	
Quadrant, n (%)			–
Upper outer	12 (57.1)	16 (48.5)	
Upper inner	3 (14.3)	5 (15.2)	
Lower outer	1 (4.8)	5 (15.2)	
Lower inner	1 (4.8)	1 (3)	
Periareolar	3 (14.3)	6 (18.2)	
Inframammary fold	1 (4.8)	0	
Imaging size**, mm, median	20	18	NS*

\* Not significant.

\*\* Ultrasound-measured size.

$\Delta T1$ ,  $\Delta T2$  and  $\Delta T3$  ( $p = 0.629$ ,  $p = 0.502$ ,  $p = 0.351$ , respectively). Variables of fibroadenoma and cysts were significantly different from malignant lesions ( $p < 0.001$ ) (Table 3).

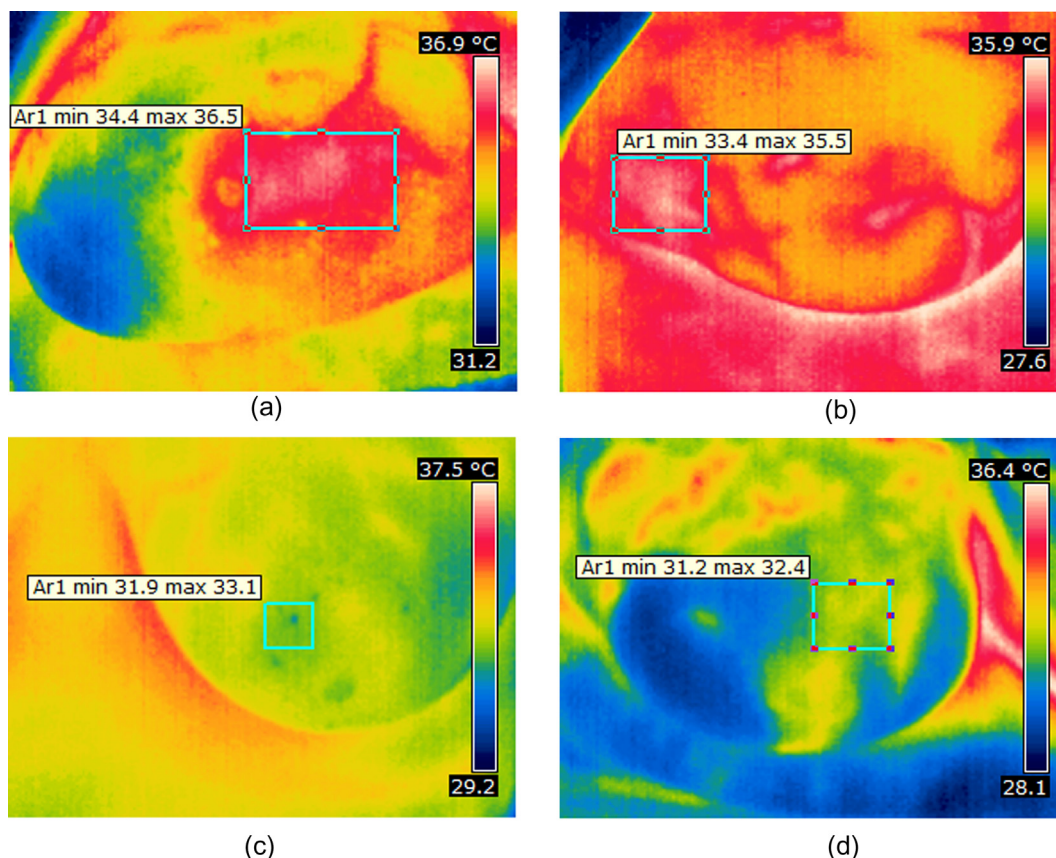
Validity of thermal imaging against conventional methods was evaluated and sensitivity, specificity, positive predictive value and negative predictive values were shown in the Table 4. They were calculated based on final histopathological evaluation. In this series of 54 patients, while conventional methods were accurate in 81.4 per cent, following 3 types of symmetry analysis, thermographic accuracy was 79.6%, 79.6% and 74%, respectively. Conventional methods showed the best area under curve value (0.848) indicating good agreement with the final diagnosis. For the same group of patients, average temperature difference analysis had a relatively lower but still fair AUC value of 0.825 (Table 4).

### 4. Discussion

Primary aim of breast cancer screening is to find a tumor at an early stage when less invasive. To be successful, the public should be aware of early detection and used screening method must be in easy reach of screening population. In this pilot study, it was hypothesized that DITI can detect abnormality in a breast using reference standard of thermal symmetry and we can use DITI in suburban and rural areas where resources are poor. Hereof, as an initial step of this process, patients who admitted with the most prevalent symptom of breast cancer in Turkey -breast-mass- were evaluated by DITI for abnormality. It was shown that DITI can play a significant role in differentiation of malign from benign lesions. Subgroup analysis revealed that it can discern difference between fibroadenoma/cysts and malignant lesions in patients with palpable breast-mass. It was also concluded that DITI was not an appropriate technique for the evaluation of granulomatous mastitis. Since fibroadenomas are mostly seen in younger women, emergence of thermal symmetry analysis as an adjunct method in symptomatic patients with dense breasts seems most promising and important.

Temperature measurement has been in practice for medical diagnosis since Hippocrates. The story of thermal imaging for medical use began in late 1950's and since then much research has been put into detecting breast abnormality by thermal devices. The first observation of raised skin temperature due to malignancy was made by Ray Lawson in 1956 [11]. A few years later Williams et al. studied 100 patients with a lump in one breast and noted that rise in overlying skin surface temperature was useful in the diagnosis of swellings [12]. Over the years, most of the researchers based their criteria upon Lawson and Williams et al.'s findings. In their study, Draper et al. criticized this approach for being inadequate to detect occult malignancies [13]. Instead, they described 4 types of thermal patterns for screening breast abnormality. In another study, Isard and colleagues studied 10,000 subjects by thermography using 3 major groups of normal patterns and reported that thermographic accuracy was 72% in symptomatic patients [14]. Unfortunately, in 1977, Feig and friends stated the accuracy rates for thermography as lower than previously reported and the medical community have started losing interest in the technique [15].

In the last two decades, advances in infrared radiation detection in conjunction with improved computer software have led to the designation of DITI systems. Nowadays, the microbolometer-based cameras provide high quality images and temperature differences across sites can be easily measured with high sensitivity and resolution using software programs. Preliminary studies have reported promising results for DITI in diagnosis of breast cancer. In a 4-year clinical trial, Parisky et al. evaluated efficacy of DITI in patients with suspicious lesion on mammography and reported sensitivity of 97%, specificity of 14%, negative predictive value of 95% and positive predictive value of 24% [16]. They also noted that specificity of the method was statistically better in evaluation of mass lesions and dense breasts. In a study from United Kingdom, thermography expert review of lesion site was shown to be highly satisfactory with a sensitivity of 78% and a specificity of



**Fig. 2.** (A–D) Coronal plane thermographic images. White rectangles indicate the areas of temperature measurement and also corresponding pathological mass lesion. (A) Patient with granulomatous mastitis in the 3 o'clock position of the right breast in the periareolar region. Ultrasound definition was multiple clustered hypoechoic lesion measuring 47 mm. (B) Patient with invasive ductal carcinoma in the axillary tail of the right breast. Ultrasound definition was irregular spiculated hypoechoic mass measuring 30 mm. (C) Patient with 18 mm fibroadenoma in the left breast at 11 o'clock. (D) Patient with 27 mm cyst in the right breast at 1 o'clock.

**Table 2**  
Temperature distribution of malignant and benign lesions. Bold values indicate statistical significance.

	Invasive ductal carcinoma	Fibroadenoma	Granulomatous mastitis	Cyst	p <sup>1</sup>	p <sup>2</sup>	p <sup>3</sup>
Minimum	34.6 ± 0.7	33.4 ± 1.4	35.5 ± 1.1	32.8 ± 2	<b>.019</b>	.368	.106
Average	35.1 ± 0.7	33.8 ± 1.4	36 ± 1	33.2 ± 1.8	<b>.008</b>	.365	.066
Maximum	35.5 ± 0.7	34.2 ± 1.3	36.3 ± 0.9	33.6 ± 1.7	<b>.004</b>	.390	<b>.049</b>

P<sup>1</sup>: Comparison of mean minimum temperature values of invasive ductal carcinoma and fibroadenoma.

P<sup>2</sup>: Comparison of mean average temperature values of invasive ductal carcinoma and granulomatous mastitis.

P<sup>3</sup>: Comparison of mean maximum temperature values of invasive ductal carcinoma and cyst.

**Table 3**  
Comparison of temperature gradients among lesions.

	ΔT1*	ΔT2**	ΔT3***
	Mean ± SD, Median (min,max)		
Malignant	1.5 ± 0.8, 1.5(-.2,3.5)	1.7 ± 0.8, 1.6(0,3.6)	1.8 ± 0.7, 1.6(0.5,3.3)
Fibroadenoma	0.2 ± 0.6, 0.2(-.6,1.9)	0.3 ± 0.5, .02(-.5,1.6)	0.3 ± 0.4, 0.4(-.5,1.4)
Granulomatous mastitis	1.1 ± 0.7, 0.9(0.4,2.4)	1.3 ± 0.6, 1.1(0.6,2.3)	1.3 ± 0.5, 1.2(0.8,2.2)
Cyst	± 0.3, 0(-0.8,0.4)	± 0.4, 0.1(-1.1,0.3)	± 0.4, 0.2(-0.9,0.6)

\* A difference in minimum temperature of lesion site and mirror image site.

\*\* A difference in average temperature of lesion site and mirror image site.

\*\*\* A difference in maximum temperature of lesion site and mirror image site.

48% for breast cancer detection [17]. In their study, Ng and friends concluded that thermography could be more accurate in patients with breast complaints or positive screening test [18]. According to the research of Sterns and friends, bigger tumor size, aggressive

characteristics and relatively large regional vessels were associated with thermographic abnormality [19]. In the light of the late studies, promotion of thermal imaging procedure in symptomatic young population seems most appropriate and advantageous.

**Table 4**

Comparison of sensitivity, specificity, positive predictive value and negative predictive value of both conventional methods and three types of thermal imaging procedure.

	AUC	Sensitivity	Specificity	Positive predictive value	Negative predictive value
ΔT1	0.816	90.48%	72.73%	67.86%	92.31%
ΔT2	0.825	95.24%	69.70%	66.67%	95.83%
ΔT3	0.779	95.24%	60.61%	60.61%	95.24%
Conventional methods	0.848	100.00%	69.70%	67.74%	100.00%

AUC: Area under curve.

Recently, research in thermal image processing contains image enhancement, pattern classification and analyses of asymmetry [20]. The technique adopted in this study is primarily based on thermal asymmetry. This might be a differentiating characteristic between this study and the most of the previous reports. Early studies mostly tried to determine abnormal patterns and focused on reading them. This can be attributed to the simplicity of the first thermal devices. There have been several studies using DITI for asymmetry analysis in breast cancer study. In their series, Keyserling and friends regarded 1 °C focal increase between lesion and its mirror image site as an abnormal sign [21]. Again, in their interpretive model derived from the Ville Marie infrared grading scale, Wang et al. used 1 °C as a reference cut-off and reported AUC value of 0.699 [22]. In another research with long follow-up period, Ohsumi and his colleagues evaluated prognostic value of DITI in patients with breast cancer by calculating the mean temperature differences between the quadrant of tumor and its mirror image [23]. They identified the cut-off value as 0.9 °C and demonstrated that the difference of two mean temperatures was an independent prognostic factor of breast cancer. Although these research projects have shown valuable performance, the fundamental idea behind the preferred cut-off values is not clear.

One of the few studies establishing thermal symmetry for healthy subjects was Yang et al.'s report in 2007 [24]. They indicated that between the two breasts of a healthy subject, the mean 0.5 °C difference in a thermography was normal. If a thermography exceeds that reference, they mentioned abnormality and suggested further examination of the patient. In this pilot study, we aimed to determine potential of this objective method in patients with breast-mass complaints. We anticipated that due to processes of angiogenesis, inflammation and rising nitric oxide levels primarily caused by malignancy, skin surface temperature difference between a lesion and its mirror image site would exceed reference cut-off and we could use that variation for the diagnosis of malignant lesions [25]. In this group of patients, we have shown that DITI can diagnose breast lump with sensitivity up to 95.24% and specificity up to 72.73% when 0.5 °C is taken as a reference point for symmetry. Even though few other studies have shown better performance, either their methodology is not clear or their criteria is too complicated to reproduce [26].

Granulomatous mastitis is a rare entity that can -both clinically and radiologically- mimic breast carcinoma, thus accurate diagnosis is demanding [27,28]. Since the first identification by Kessler and Wolloch, much of research has been conducted to elucidate etiology, diagnosis and management of this condition [29]. Experience from the literature so far indicates that the triple assessment is adequate in differentiation of GM from malignant lesions [30]. Although the proposed model for DITI was efficacious in differentiation of fibroadenoma and cysts from malignant lesions, it was inconclusive in granulomatous mastitis. Probably due to triggered inflammatory response, they were not different than malign lesions in terms of thermal signs.

Altogether, this study provides baseline evidence for future randomized studies. The established criterion for thermal symmetry of

breasts along with orientation of the thermal interpreter to the region of interest was at the level of being diagnostic in patients with palpable breast mass. Using temperature gradient as a variable, patients who could likely benefit from this technique are those with palpable breast mass without associated features of inflammation including younger women and patients with dense breasts. Future studies using DITI devices for asymptomatic patients should also be conducted to recommend it as a screening method in rural areas.

## 5. Declarations of interest

None.

## 6. Disclosure statement

We wish to confirm that there are no known conflicts of interest associated with this publication and there has been no significant financial support for this work that could have influenced its outcome.

## Appendix A. Supplementary material

Supplementary data associated with this article can be found, in the online version, at <https://doi.org/10.1016/j.infrared.2018.04.019>.

## References

- [1] V. Ozmen, Breast cancer in the world and Turkey, *J. Breast Health*. 4 (2008) 6–12.
- [2] F.A. Mettler, *Essentials of Radiology*, second ed. Elsevier Saunders, Philadelphia, 2005, xi, 416 p.
- [3] P. Crystal, S.D. Strano, S. Shcharynski, M.J. Koretz, Using sonography to screen women with mammographically dense breasts, *Am. J. Roentgenol.* 181 (1) (2003) 177–182.
- [4] K. Kerlikowske, D. Grady, J. Barclay, E.A. Sickles, V. Ernster, Effect of age, breast density, and family history on the sensitivity of first screening mammography, *JAMA* 276 (1) (1996) 33–38.
- [5] L. Ma, E. Fishell, B. Wright, W. Hanna, S. Allan, N.F. Boyd, Case-control study of factors associated with failure to detect breast cancer by mammography, *J. Natl Cancer Inst.* 84 (10) (1992) 781–785.
- [6] Turkey Cancer Control Programme Ankara: Turkey Public Health Institution Cancer Control Department; 201 Available from: [kanser.gov.tr/Dosya/Kitaplar/turkce/Turkiye\\_Kanser\\_Kontrol\\_Program\\_ing.pdf](http://kanser.gov.tr/Dosya/Kitaplar/turkce/Turkiye_Kanser_Kontrol_Program_ing.pdf).
- [7] M. Etehadtavakol, E.Y.K. Ng, Breast thermography as a potential non-contact method in the early detection of cancer: a review, *J. Mech. Med. Biol.* 13 (02) (2013) 1330001.
- [8] M. Anbar, Clinical thermal imaging today, *IEEE Eng. Med. Biol. Mag.* 17 (4) (1998) 25–33.
- [9] E.Y. Ng, Y. Chen, L.N. Ung, Computerized breast thermography: study of image segmentation and temperature cyclic variations, *J. Med. Eng. Technol.* 25 (1) (2001) 12–16.
- [10] I. Fernández-Cuevas, J.C. Bouzas Marins, J. Arnáiz Lastras, P.M. Gómez Carmona, S. Piñonosa Cano, M.Á. García-Concepción, et al., Classification of factors influencing the use of infrared thermography in humans: a review, *Infrared Phys. Technol.* 71 (2015) 28–55.
- [11] R. Lawson, Implications of surface temperatures in the diagnosis of breast cancer, *Can. Med. Assoc. J.* 75 (4) (1956) 309–311.
- [12] K.L. Williams, F.J. Williams, R.S. Handley, Infra-red thermometry in the diagnosis of breast disease, *Lancet* 2 (7217) (1961) 1378–1381.
- [13] J.W. Draper, C.H. Jones, Thermal patterns of the female breast, *Br J Radiol.* 42 (498) (1969) 401–410.
- [14] H.J. Isard, W. Becker, R. Shilo, B.J. Ostrum, Breast thermography after four years and 10000 studies, *Am. J. Roentgenol. Radium. Ther. Nucl. Med.* 115 (4) (1972) 811–821.
- [15] S.A. Feig, G.S. Shaber, G.F. Schwartz, A. Patchefsky, H.I. Libshitz, J. Edeiken, et al., Thermography, mammography, and clinical examination in breast cancer screening. Review of 16,000 studies, *Radiology* 122 (1) (1977) 123–127.
- [16] Y.R. Parisky, A. Sardi, R. Hamm, K. Hughes, L. Esserman, S. Rust, et al., Efficacy of computerized infrared imaging analysis to evaluate mammographically suspicious lesions, *AJR Am. J. Roentgenol.* 180 (1) (2003) 263–269.
- [17] G.C. Wishart, M. Campisi, M. Boswell, D. Chapman, V. Shackleton, S. Iddles, et al., The accuracy of digital infrared imaging for breast cancer detection in women undergoing breast biopsy, *Eur. J. Surg. Oncol.* 36 (6) (2010) 535–540.
- [18] E.Y. Ng, L.N. Ung, F.C. Ng, L.S. Sim, Statistical analysis of healthy and malignant breast thermography, *J. Med. Eng. Technol.* 25 (6) (2001) 253–263.
- [19] E.E. Sterns, B. Zee, S. SenGupta, F.W. Saunders, Thermography. Its relation to pathologic characteristics, vascularity, proliferation rate, and survival of patients with invasive ductal carcinoma of the breast, *Cancer* 77 (7) (1996) 1324–1328.
- [20] H. Qi, N.A. Diakides, Thermal Infrared Imaging in Early Breast Cancer Detection, in: R.I. Hammoud (Ed.), *Augmented Vision Perception in Infrared: Algorithms and*

- Applied Systems, Springer, London, 2009, pp. 139–152.
- [21] J.R. Keyserlingk, P.D. Ahlgren, E. Yu, N. Belliveau, Infrared imaging of the breast: initial reappraisal using high-resolution digital technology in 100 successive cases of stage I and II breast cancer, *Breast J.* 4 (4) (1998) 245–251.
- [22] J. Wang, K.J. Chang, C.Y. Chen, K.L. Chien, Y.S. Tsai, Y.M. Wu, et al., Evaluation of the diagnostic performance of infrared imaging of the breast: a preliminary study, *Biomed. Eng. Online* 9 (2010) 3.
- [23] S. Ohsumi, S. Takashima, K. Aogi, H. Usuki, Prognostic value of thermographical findings in patients with primary breast cancer, *Breast Cancer Res. Treat.* 74 (3) (2002) 213–220.
- [24] H.-q. Yang, S.-S. Xie, Q.-Y. Lin, Z. Ye, S.-Q. Chen, H. Li, editors. A new infrared thermal imaging and its preliminary investigation of Breast Disease Assessment. *Complex Medical Engineering, 2007 CME 2007 IEEE/ICME International Conference on; 2007: IEEE.*
- [25] M. Anbar, Hyperthermia of the cancerous breast: analysis of mechanism, *Cancer Lett.* 84 (1) (1994) 23–29.
- [26] C.R. Nicandro, M.M. Efren, A.A. Maria Yaneli, M.D. Enrique, A.M. Hector Gabriel, P.C. Nancy, et al., Evaluation of the diagnostic power of thermography in breast cancer using Bayesian network classifiers, *Comput. Math. Methods Med.* 2013 (2013) 264246.
- [27] S. Prasad, P. Jaiprakash, A. Dave, D. Pai, Idiopathic granulomatous mastitis: an institutional experience, *Turk. J. Surg.* 33 (2) (2017) 100–103.
- [28] B.K. Han, Y.H. Choe, J.M. Park, W.K. Moon, Y.H. Ko, J.H. Yang, et al., Granulomatous mastitis: mammographic and sonographic appearances, *AJR Am. J. Roentgenol.* 173 (2) (1999) 317–320.
- [29] E. Kessler, Y. Wolloch, Granulomatous mastitis: a lesion clinically simulating carcinoma, *Am. J. Clin. Pathol.* 58 (6) (1972) 642–646.
- [30] B. Al-Khaffaf, F. Knox, N.J. Bundred, Idiopathic granulomatous mastitis: a 25-year experience, *J. Am. Coll. Surg.* 206 (2) (2008) 269–273.