



# Calcinosis in scleroderma

Antonia Valenzuela<sup>a</sup>, Paula Song<sup>b</sup>, and Lorinda Chung<sup>c</sup>

## Purpose of review

To provide an update on the available literature regarding the epidemiology, pathophysiology, diagnosis, and treatment of calcinosis cutis in patients with systemic sclerosis (SSc).

## Recent findings

We identified observational studies that describe the frequency of calcinosis in SSc and associated clinical features; molecular studies exploring potential pathogenic mechanisms; and case reports and case series describing new diagnostic approaches and treatments.

## Summary

Calcinosis cutis is the deposition of insoluble calcium in the skin and subcutaneous tissues. It represents a major clinical problem in patients with SSc affecting at least one quarter of patients. It is associated with longer disease duration, digital ulcers, acro-osteolysis, positive anticentromere antibody, and positive anti-PM/Scl antibody. Although pathogenesis is unknown, there is evidence supporting local trauma, chronic inflammation, vascular hypoxia, and dysregulation of bone matrix proteins as potential mechanisms. Diagnosis can be made clinically or with plain radiography. Several pharmacologic therapies have been tried for calcinosis with variable and modest results, but surgical excision of calcium deposits remains the mainstay of treatment.

## Keywords

calcifications, calcinosis cutis, systemic sclerosis

## INTRODUCTION

Calcinosis cutis is the deposition of insoluble calcium in the skin and subcutaneous tissues [1] (Fig. 1). There are five subtypes of calcinosis: dystrophic, metastatic, iatrogenic, idiopathic, and calciophylaxis [2]. Dystrophic calcinosis is the subtype associated with autoimmune connective tissue diseases (ACTD) [3] such as systemic sclerosis (SSc) [4]. Although the detailed pathophysiology of calcinosis cutis remains poorly understood, the general mechanism for dystrophic calcinosis is the deposition of calcified material in damaged tissue in the setting of normal serum calcium and phosphate levels [5]. We will review the most current literature regarding associated clinical factors, pathogenesis, diagnostic approach, and treatment options for dystrophic calcinosis as seen in SSc.

## EPIDEMIOLOGY AND ASSOCIATED CLINICAL FACTORS

The prevalence of calcinosis in SSc ranges from 18 to 49%. This large range is likely attributable to variable definitions based on clinical and/or radiographic assessments, and differences in patient populations [6<sup>a</sup>,7<sup>\*\*\*</sup>,8–10]. The prevalence increases

in people who have had SSc for a prolonged duration, as calcinosis typically occurs more than 10 years after diagnosis [4,11]. Small single-center studies showed that factors associated with calcinosis include male sex, digital ulcers, digital pitting scars, acro-osteolysis, telangiectasias, anticentromere antibody (ACA), and anti-PM/Scl antibody [8,10,12–15]. An international cohort study of 5218 patients later confirmed the association of calcinosis with digital ulcers, telangiectasias, and ACA along with discovering a novel association with osteoporosis [16].

<sup>a</sup>Stanford University School of Medicine, Division of Immunology and Rheumatology, Palo Alto, California, <sup>b</sup>Santa Clara Valley Medical Center, Department of Medicine, San Jose, California and <sup>c</sup>Stanford University School of Medicine and Palo Alto VA Healthcare System, Division of Immunology and Rheumatology, and Dermatology, Palo Alto, California, USA

Correspondence to Dr Lorinda Chung, MD, MS, Stanford University School of Medicine, Department of Immunology and Rheumatology, 1000 Welch Road, Suite 203 MC 5755, Palo Alto, CA 94304, USA. Tel: +1 650 736 0727; fax: +1 650 723 9656; e-mail: shauwei@stanford.edu

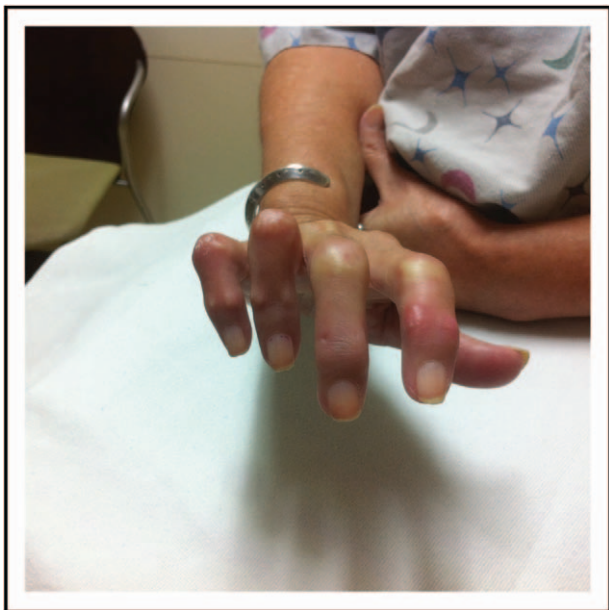**Curr Opin Rheumatol** 2018, 30:554–561

DOI:10.1097/BOR.0000000000000539

## KEY POINTS

- Calcinosis is a common and potentially debilitating manifestation in patients with SSc, most frequently affecting the hands, and particularly the fingers.
- Clinical features found to be associated with calcinosis in SSc in observational studies are longer disease duration, digital ulcers, acro-osteolysis, positive ACA, and positive anti-PM/Scl antibody.
- Diagnosis can be made clinically or with plain radiography. There is also growing evidence for the use of ultrasonography in evaluating calcinosis in SSc.
- The detailed pathophysiology of calcinosis cutis remains unclear, but there is evidence supporting chronic inflammation, vascular hypoxia, local trauma, and dysregulation of bone matrix proteins as potential mechanisms.
- Several medications have been described with variable results, but surgery remains the mainstay for the treatment of calcinosis.

Recent studies have shown different clinical associations with calcinosis based on the population studied. In a single-center study of 215 SSc patients in the United States, calcinosis was associated with limited cutaneous SSc (lcSSc) [17<sup>\*\*\*</sup>]. In Mexican and Malaysian cohorts, calcinosis was associated with diffuse cutaneous SSc (dcSSc) [7<sup>\*\*\*</sup>,18]. Antinucleolar and anti-Scl-70 antibodies were more prevalent and ACA was less prevalent in Mexican patients with calcinosis [7<sup>\*\*\*</sup>]. Similarly, dcSSc and antitopoisomerase (Scl-70)



**FIGURE 1.** Calcinosis of the hand, overlying contracted joints that have frequently been traumatized.

antibody were predictors of calcinosis in a cohort of 1305 SSc patients from the Canadian Scleroderma Research Group (CSRG) registry, which includes patients from Canada and Mexico [10]. However, in a multicenter study of 1009 African Americans with SSc, no associations were seen with cutaneous subtype, male sex, or ACA [6<sup>\*</sup>].

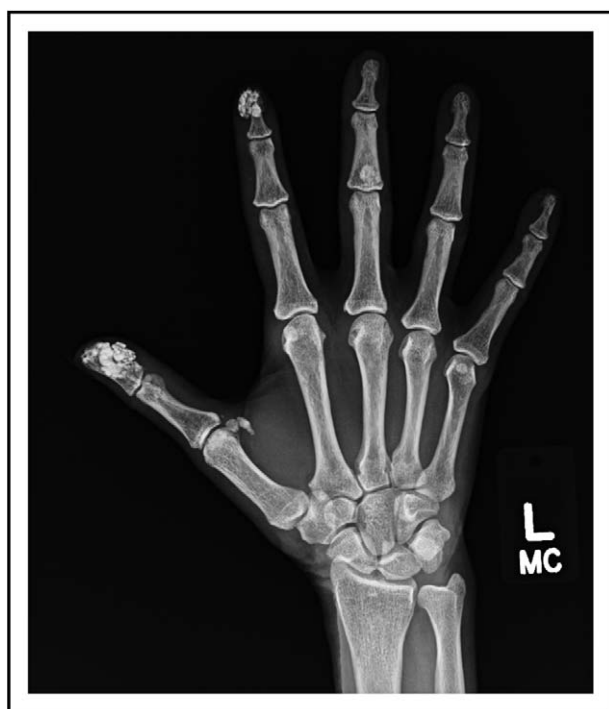## CLINICAL PRESENTATION

Calcinosis in SSc presents as subcutaneous nodules in digits or in pressure point areas such as elbows, knees, or ischial tuberosities. Calcinosis occurs most frequently in the hands (65–83%), proximal upper extremity (27%), knee or proximal lower extremity (10–22%), and hip (6.7%) [7<sup>\*\*\*</sup>,19]. Calcinosis can also affect the trunk, chest, and buttocks, and more obscure locations such as the maxillary sinuses, spine, and paraspinal tissues [7<sup>\*\*\*</sup>,20]. Calcinosis may be painful and accompanied by soft tissue swelling, ulcers with superimposed infection, or deformities particularly in the hands leading to functional limitations [2,20,21]. Patients may also complain of a ‘toothpaste-like’ material extruding from the skin, which can be a point of entry for infections.

## DIAGNOSIS

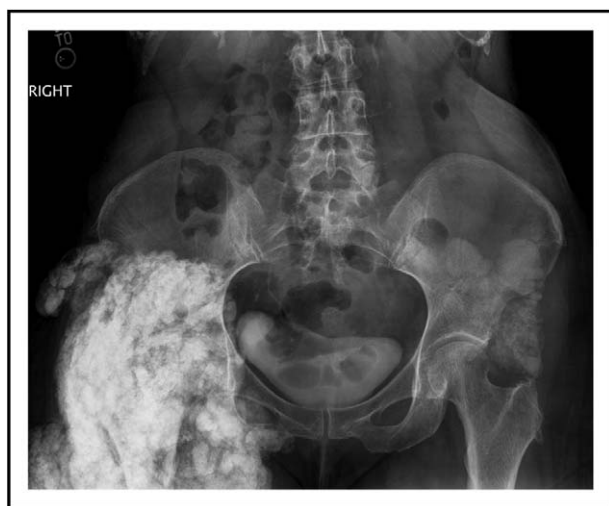
Although calcinosis is often clearly palpable or visible on physical examination, imaging can help confirm the diagnosis of subclinical deposits. Plain radiography is sensitive in detecting calcinosis and is the first-line imaging modality for evaluation in patients with ACTD [22] (Figs. 2 and 3). A radiographic scoring system for hand calcinosis was recently developed and validated that may standardize the measurement of calcium deposits for clinical and research purposes [24]. This scoring system takes into account the body area covered, density, number, and anatomic location of calcinosis lesions to provide an estimate of calcinosis burden, with excellent inter-rater and intra-rater reliability. Another method of categorizing calcinosis has also been proposed based on clinical and radiographic shapes and patterns of the lesions [19]. This approach divides calcinosis into four subtypes: mousse, stone, net, and plate. The authors showed that the net form took the longest time to heal (mean  $140 \pm 22$  days), whereas stone calcinosis took the shortest ( $30 \pm 12$  days), suggesting that this categorization has clinical significance in the management and prognosis of calcinosis.

There is also growing evidence for the use of ultrasound in evaluating calcinosis in SSc. Freire *et al.* showed that ultrasound has a sensitivity of 89% in detecting calcinosis [25], with no significant



**FIGURE 2.** 'Wet cotton-wool appearance' of calcinosis on radiography of the hands. Reproduced with permission from [23].

difference in calcinosis detection when compared to radiography [26]. A recent study of 10 SSc patients proposed the use of Power Doppler to detect inflammation around calcium deposits, thus identifying lesions that may be targeted with anti-inflammatory medications [27]. In addition, an ultrasound



**FIGURE 3.** Frontal radiograph of the pelvis in a 57-year-old female with systemic sclerosis demonstrates severe calcinosis around the right hip and surrounding soft tissues. Calcium deposition is also seen affecting the left hip and left hemipelvis.

technology used to detect micro-calcifications in breast tissue has been reported to differentiate hydroxyapatite deposits, as seen in SSc, from other types of calcifications [28].

Other experimental modalities include multi-detector computed tomography (MDCT), dual-energy computed tomography (DECT), and MRI. MDCT may better assess the extent of calcinotic lesions as a result of improved resolution and 3D capabilities compared to traditional CT [29]. A study of DECT in 16 SSc patients demonstrated successful detection of calcinosis in the subcutaneous tissue, tendon sheaths, carpal tunnel, and adjacent to muscles [30]. MRI can detect calcinosis deposits as well, providing better visualization of edema or inflammation of surrounding tissue that may indicate calcinosis development [31].

### **PATHOPHYSIOLOGY**

The pathophysiology behind dystrophic calcification is incompletely understood. However, several mechanisms have been proposed, including chronic inflammation, vascular hypoxia, recurrent trauma, and abnormalities in bone matrix proteins. Elevated levels of serum interleukin-1, interleukin-6, interleukin-1 $\beta$ , and tumor necrosis factor (TNF)- $\alpha$  have been found in juvenile dermatomyositis (JDM) calcinosis, supporting the role of inflammation in calcinosis development [32].

Evidence suggests that vascular ischemia also contributes to calcinosis development. Davies *et al.* demonstrated increased expression of the hypoxia-associated glucose transporter molecule (GLUT-1) in skin biopsies of SSc patients with calcinosis [33]. Additionally, several studies [16] have shown that the presence or history of digital ulcers [10,34] and/or acro-osteolysis [12–14] predicts calcinosis development. Another study showed that upregulation of VEGF, a potent angiogenic factor induced by hypoxia, was associated with increased osteoclast activity in SSc patients with acro-osteolysis, 73% of whom had calcinosis [35<sup>\*\*</sup>]. This hypoxia-induced osteoclast activity in SSc may also be involved in development of calcinosis, possibly explaining the association between calcinosis and osteoporosis [16,17<sup>\*\*</sup>,36].

Calcinosis preferentially affects the dominant hand and other acral sites, which suggests that repetitive trauma can contribute to calcinosis development [37<sup>\*\*</sup>]. These areas of recurrent trauma may be more susceptible due to the impaired compensatory angiogenesis that characterizes the proliferative obliterative vasculopathy seen in SSc [38,39<sup>\*\*</sup>].

Davies *et al.* also found increased expression of bone matrix proteins, such as osteonectin and



matrix gamma-carboxyglutamic acid protein (MGP), in calcinotic skin of SSc patients [40]. These proteins are involved in ectopic calcification via upregulation of osteonectin, an activator of calcification, in the setting of suppressed levels of the inhibitor protein MGP [41,42]. MGP must also be in its gamma-carboxylated form and bind to bone morphogenic protein-2 to inhibit calcification. This carboxylated form is vitamin K dependent [43]. Wallin *et al.* have proposed mechanisms in which oxidative stress, which is critical to microvascular injury in SSc, may inhibit vitamin K, resulting in under-gamma-carboxylated and inactive MGP, and thus dysregulated calcification [44].

Further studies are necessary to better define these mechanisms and elucidate others that contribute to the development of calcinosis in SSc.

## TREATMENT

### General measures and supportive therapies

Calcinosis remains a therapeutic challenge in patients with SSc. General measures include improving blood flow to the extremities by avoiding trauma, stress, and cold exposure. If there is suspicion for superinfection of calcinotic lesions, antibiotics covering streptococci and staphylococci should be prescribed. Acetaminophen, nonsteroidal anti-inflammatory agents, and even opioids [45] may be used to alleviate pain. If calcinosis becomes ulcerated, standard wound care with hydrocolloid membrane products may be useful [46].

### Medical therapies

Several medications have been described in the management of calcinosis, with variable results [47]. The evidence supporting these mainly comes from small retrospective studies, case series, and case reports (Table 1).

### Calcium channel blockers

Calcium channel blockers (CCBs) reduce the intracellular calcium influx in the affected tissues, altering the formation and crystallization of the calcium nidus. Diltiazem is the most used and studied CCBs for treating calcinosis. Early case reports showed encouraging results with 240 to 480 mg/day of diltiazem for calcinosis in SSc patients [48–50], which was confirmed in a retrospective cohort of 78 patients with ACTD from the Mayo Clinic showing that diltiazem was effective in 9 of 17 patients as first-line therapy [51]. However, a larger retrospective study did not show a beneficial effect on radiographs from 12 SSc patients treated with 180 mg/day

of diltiazem for 1 to 15 years [8]. An observational study using 5-year follow-up data from CSRG showed no significant associations between the use of CCBs and calcinosis [odds ratios (OR) 0.9, 95% confidence interval (CI) 0.73–1.05], except in patients with disease duration less than 5 years, in whom the use of CCBs was associated with decreased risk of calcinosis (OR 0.62, 95% CI 0.45–0.86) [52\*].

### Bisphosphonates

Bisphosphonates may be useful in reversing the calcification process by inhibiting macrophage proinflammatory cytokine production and reducing bone resorption [53]. Anecdotal reports describe improvement of calcinosis with intravenous pamidronate in patients with JDM [54–56], and adult dermatomyositis [57]. Similarly, a case series showed partial reduction of calcinosis with alendronate therapy in six of nine JDM patients [58]. A case report describes resolution of calcinosis in a patient with lcSSc after 6 months of risedronate therapy for glucocorticoid-induced osteoporosis [59]. Given the paucity of evidence, the efficacy of bisphosphonates in calcinosis treatment remains unclear.

### Warfarin

Low-dose warfarin has been used for treatment of ACTD-calcinosis, based on the rationale that it reduces the levels of MGP by preventing carboxylation of glutamic acid [20]. A case series of three SSc patients treated with warfarin, described resolution of calcinosis in two patients after 1 year [60]. In the Mayo Clinic study, four of 19 patients with calcinosis and ACTD taking warfarin for other indications had no changes in calcinosis compared with the group that did not receive warfarin [51]. In another study of six patients with extensive calcinosis (one with SSc) treated with warfarin for 14.6 months, five had worsening of calcinosis [61]. Indeed, there is some concern that warfarin can promote calcification through under-carboxylated MGP [20,62].

### Sodium thiosulfate

Topical, intralesional and intravenous sodium thiosulfate (STS) have been studied as treatments for calcinosis [63]. A report describes two cases of ulcerative dystrophic calcinosis refractory to topical treatments that had excellent responses to topical 25% STS compounded in zinc oxide [64]. Four patients with calcinosis (one with SSc and two with dermatomyositis) showed significant decrease in size, erythema, and pain with topical 25% sodium metabisulfite (SM), a metabolite of STS. The authors hypothesized that topical SM may dissolve calcium

**Table 1.** Pharmacological treatments of calcinosis in systemic sclerosis

Treatment	Rationale/biology	Drug/dosage	Number of responses/numbers of patients treated	Authors recommendations	References	
Calcium channel blockers	Reduce intracellular calcium influx in the affected tissues and local macrophages	Diltiazem 240–480 mg/day × 1–12 years	4/4	Moderate	Palmieri <i>et al.</i> [48]	
		120 mg/day × 2 years	1/1		Dolan <i>et al.</i> [49]	
		240 mg /day × 5 years	1/1		Farah <i>et al.</i> [50]	
Bisphosphonates	Inhibit macrophage proinflammatory cytokine production and reduce calcium turnover	Risedronate × 6 months	1/1	Low	Fujii <i>et al.</i> [59]	
Warfarin	Inhibits the production of gamma-carboxyglutamic acid, which has calcium-binding properties	1 mg/day × 1 year 1 mg/day × 7–28 months	2/3 0/1	Low	Cukierman <i>et al.</i> [60] Lassoued <i>et al.</i> [61]	
Sodium thiosulfate (STS)	Potent antioxidant and vasodilator that also chelates and dissolves calcium deposits	Topical: STS 25% compounded in zinc oxide	2/2	Moderate	Bair <i>et al.</i> [64]	
		25% sodium metabisulfite	1/1		Barrio-Diaz <i>et al.</i> [65]	
		Intralesional: STS 1–3 g × 1 year	2/2		Goosens <i>et al.</i> [66]	
		STS 12.5–150 mg × 1–4 times	5/5		Baumgartner-Nielsen <i>et al.</i> [67]	
Anti-TNF	Potential role of inflammation and TNF-alpha in calcinosis	Intravenous: 20 g/day, 5 days/month, at least six cycles	0/1	Moderate	Mageau <i>et al.</i> [69]	
		Infliximab 3 mg/kg intravenous at 0, 2, and 6 weeks, and every 8 weeks × 7 months	1/1		Low	Tosonidou <i>et al.</i> [70]
		Rituximab 375 mg/m <sup>2</sup> intravenous weekly × 4	1/1		Low	De Paula <i>et al.</i> [71]
		Rituximab 375 mg/m <sub>2</sub> intravenous weekly × 4	3/6			Giugglioli <i>et al.</i> [72]
Rituximab	Chimeric anti-CD20 antibody that depletes B lymphocytes	1 gram intravenous × 2 at 2 week-interval and then every 6 months	0/1	Moderate	Hurabielle <i>et al.</i> [73]	
		1 gram intravenous × 2 at 2 week-interval and then every year	0/1		Dubos <i>et al.</i> [74]	
		375 mg/m <sup>2</sup> intravenous weekly × 4	0/1		Dubos <i>et al.</i> [74]	
Minocycline	Tetracycline antibiotic with anti-inflammatory and calcium-binding properties	50–100 mg/day for 3.5 years	8/9	High	Robertson <i>et al.</i> [75]	
Ceftriaxone	Third-generation cephalosporin able to bind calcium ions, and form insoluble calcium complexes	2 grams intravenous × 20 days	1/1	Low	Reiter <i>et al.</i> [76]	
Aluminum hydroxide	Decreases serum phosphate levels by decreasing intestinal absorption thus reducing the calcification process	30 ml orally 4 times per day	1/1	Low	Hudson <i>et al.</i> [77]	
Triamcinolone acetonide injection	Anti-inflammatory effect	Intralesional 20 mg/ml every 4–8 weeks × 6 months	1/1	Moderate	Hazen <i>et al.</i> [78]	
Colchicine	Anti-inflammatory effect by disrupting leukocyte chemotaxis and phagocytosis through inhibiting microtubule polymerization	1 mg daily × 2 months	1/1	Moderate	Fuchs <i>et al.</i> [79]	
		1 mg daily × 4 months	1/1		Vereecken <i>et al.</i> [80]	
Intravenous immunoglobulin	Effect based on anti-inflammatory properties, possibly related to suppression of activated macrophages	2 g/day in a 4-day protocol once a month × 5 cycles	1/1	Moderate	Schanz <i>et al.</i> [81]	

deposits and promote local vasodilation and wound healing [65]. Goossens *et al.* reported two cases of weekly intralesional injections of 1–3 g STS leading to pain relief, functional improvement, and 59% size reduction after 12 months [66]. A larger series describes the treatment of eight lesions in six patients (five with SSc and one with nephrogenic systemic fibrosis) with injections of 12.5–275 mg STS 150 mg/ml for up to 4 weeks. By weeks 4 and 12, the lesions decreased in size by 67% and 90%, respectively, and all patients reported improved pain and disability [67]. A report of three patients with ACTD-associated calcinosis treated with intravenous STS, after failing multiple prior therapies, did not show any notable clinical improvement of calcinosis [68]. However, another series of four patients (lcSSc, dermatomyositis, JDM, SLE) demonstrated improvement in calcinosis after 6 cycles of intravenous STS except in the patient with lcSSc [69]. More research is needed to evaluate STS as an option for calcinosis treatment.

### Biologic agents

A patient with SSc-myositis overlap and refractory calcinosis treated with infliximab 3 mg/kg infused at 0, 2 and 6 weeks, and every 8 weeks thereafter, showed reduction in size of calcifications and no new deposits at 41 months in serial CT imaging [70].

Most literature on biologics for calcinosis has focused on rituximab (RTX). A case report showed RTX given in four weekly infusions (375 mg/m<sup>2</sup>) improved or completely resolved calcinotic lesions [71]. Additionally, a series of 10 SSc patients treated with RTX for ILD, skin fibrosis and/or arthritis, reported improvement in three of six patients who had calcinosis [72]. However, a flare of calcinosis in a patient with dcSSc who received RTX to treat underlying ILD and arthritis was recently reported [73]. Similarly, two patients treated with RTX had progression of calcinosis 6 and 12 months after treatment. At present, RTX cannot be recommended for this indication in the absence of successful controlled trials [74].

### Others

In a case series of nine lcSSc patients with calcinosis, 50 or 100 mg/day of minocycline for a mean of 3.5 years resulted in reduced ulceration and inflammation, with a modest decrease in the size of deposits in eight patients [75]. Only scattered case reports have documented the efficacy of ceftriaxone [76], aluminum hydroxide [77], triamcinolone acetonide injection [78], colchicine [51,79,80], and intravenous immunoglobulins [81] in treating SSc-calcinosis. A new potential treatment comes from preliminary

observations from the Pulmonary Hypertension Assessment and Recognition of Outcomes in Scleroderma (PHAROS) registry wherein two patients with SSc-pulmonary arterial hypertension (PAH) and calcinosis treated with subcutaneous treprostinil for PAH experienced radiographic improvement in their calcinosis lesions after 6 months (Shapiro *et al.*, unpublished data). Oral treprostinil is currently being studied in a clinical trial of SSc patients with calcinosis of the hands (NCT02663895).

### Procedures

A prospective study of nine patients (three with SSc) with calcinosis found that three hexacorporeal shock wave lithotripsy (ESWL) sessions at 3-week intervals reduced the size and pain from calcinosis at 6 months [82]. A recent 12-week study of three weekly sessions of ESWL on calcinosis lesions in four SSc patients found a reduction in lesion size in three patients and pain improvement in two patients [83].

The carbon dioxide (CO) laser-tissue vaporization procedure allows excellent visualization and vaporization of calcium deposits and has been shown to improve pain and function in selected patients with SSc-calcinosis [84,85].

Patients with large, localized, and symptomatic lesions especially located over tendons, blood vessels, and nerves should be referred for surgery [86,87<sup>\*\*\*</sup>]. In the Mayo Clinic experience, all 11 patients who underwent surgical excision alone and 16 out of 17 patients who received medical and surgical therapy responded to treatment. In contrast, only seven of 19 patients treated with medical therapy alone had any response [51]. Specific techniques such as curettage of calcinosis [88] or debulking with a high-speed micro-burr [89] effectively reduce pain and disability scores, but lesions can recur.

### CONCLUSION

Calcinosis is a common problem in patients with SSc. It most frequently affects the hands, particularly the fingers. Although pathogenesis is unclear, there is evidence supporting chronic inflammation, vascular hypoxia, local trauma, and dysregulation of bone matrix proteins as potential mechanisms. There are no universally effective medical treatments for calcinosis in patients with SSc; however, limited data have been published supporting the use of several pharmacological therapies including CCBs, bisphosphonates, warfarin, and STS. Surgical excision of calcinosis remains the mainstay for treatment. Clinical trials using novel outcome measures

are necessary to determine the efficacy of current and emerging treatments.

## Acknowledgements

None.

## Financial support and sponsorship

None.

## Conflicts of interest

There are no conflicts of interest.

## REFERENCES AND RECOMMENDED READING

Papers of particular interest, published within the annual period of review, have been highlighted as:

- of special interest
- of outstanding interest

1. Chander S, Gordon P. Soft tissue and subcutaneous calcification in connective tissue diseases. *Curr Opin Rheumatol* 2012; 24:158–164.
  2. Boulman N, Slobodin G, Rozenbaum M, Rosner I. Calcinosis in rheumatic diseases. *Semin Arthritis Rheum* 2005; 34:805–812.
  3. Walsh JS, Fairley JA. Calcifying disorders of the skin. *J Am Acad Dermatol* 1995; 33(5 Pt 1):693–706.
  4. Gutierrez A Jr, Wetter DA. Calcinosis cutis in autoimmune connective tissue diseases. *Dermatol Ther* 2012; 25:195–206.
  5. Reiter N, El-Shabrawi L, Leinweber B, et al. Calcinosis cutis: part I. Diagnostic pathway. *J Am Acad Dermatol* 2011; 65:1–12.
  6. Morgan ND, Shah AA, Mayes MD, et al. Clinical and serological features of systemic sclerosis in a multicenter African American cohort: analysis of the genome research in African American scleroderma patients clinical database. *Medicine* 2017; 96:e8980.
- This is a comprehensive retrospective and prospective clinical database of 1009 African-American patients with SSc from 18 academic centers throughout the United States, confirming association of calcinosis with longer disease duration in this subset of patients.
7. Cruz-Dominguez MP, Garcia-Collinot G, Saavedra MA, et al. Clinical, biochemical, and radiological characterization of the calcinosis in a cohort of Mexican patients with systemic sclerosis. *Clin Rheumatol* 2017; 36: 111–117.
- This study identifies and quantifies the distribution of calcinosis in a cohort of 109 Mexican patients with SSc and its association with clinical features and autoantibodies.
8. Vayssairat M, Hidouche D, Abdoucheli-Baudot N, Gaitz JP. Clinical significance of subcutaneous calcinosis in patients with systemic sclerosis. Does diltiazem induce its regression? *Ann Rheum Dis* 1998; 57:252–254.
  9. Belloli L, Ughi N, Massarotti M, et al. Role of fetuin-A in systemic sclerosis-associated calcinosis. *J Rheumatol* 2010; 37:2638–2639.
  10. Baron M, Pope J, Robinson D, et al. Calcinosis is associated with digital ischaemia in systemic sclerosis—a longitudinal study. *Rheumatology (Oxford)* 2016; 55:2148–2155.
  11. Galluccio F, Allanore Y, Czirkaj L, et al. Points to consider for skin ulcers in systemic sclerosis. *Rheumatology (Oxford)* 2017; 56(suppl\_5):v67–v71.
  12. Avouac J, Mogavero G, Guerini H, et al. Predictive factors of hand radiographic lesions in systemic sclerosis: a prospective study. *Ann Rheum Dis* 2011; 70:630–633.
  13. Johnstone EM, Hutchinson CE, Vail A, et al. Acro-osteolysis in systemic sclerosis is associated with digital ischaemia and severe calcinosis. *Rheumatology (Oxford)* 2012; 51:2234–2238.
  14. Koutaissoff S, Vanthuyne M, Smith V, et al. Hand radiological damage in systemic sclerosis: comparison with a control group and clinical and functional correlations. *Semin Arthritis Rheum* 2011; 40:455–460.
  15. Tolosa-Vilella C, Morera-Morales ML, Simeon-Aznar CP, et al. Digital ulcers and cutaneous subsets of systemic sclerosis: clinical, immunological, nailfold capillaroscopy, and survival differences in the Spanish RESCLE Registry. *Semin Arthritis Rheum* 2016; 46:200–208.
  16. Valenzuela A, Baron M, Herrick AL, et al. Calcinosis is associated with digital ulcers and osteoporosis in patients with systemic sclerosis: a scleroderma clinical trials consortium study. *Semin Arthritis Rheum* 2016; 46:344–349.
  17. Pai S, Hsu V. Are there risk factors for scleroderma-related calcinosis? *Mod Rheumatol* 2018; 28:518–522.

This cross-sectional study was performed to better understand the prevalence and clinical features associated with calcinosis in a single-center cohort of 215 SSc outpatients. Longer disease duration and osteoporosis were independently associated with calcinosis.

18. Sujau I, Ng CT, Sthaneshwar P, et al. Clinical and autoantibody profile in systemic sclerosis: baseline characteristics from a west Malaysian cohort. *Int J Rheum Dis* 2015; 18:459–465.
  19. Bartoli F, Fiori G, Braschi F, et al. Calcinosis in systemic sclerosis: subsets, distribution and complications. *Rheumatology (Oxford)* 2016; 55:1610–1614.
  20. Herrick AL, Gallas A. Systemic sclerosis-related calcinosis. *J Scleroderma Relat Disord* 2016; 1:194–203.
  21. Vitiello M, Abuchar A, Santana N, et al. An update on the treatment of the cutaneous manifestations of systemic sclerosis: the dermatologist's point of view. *J Clin Aesthet Dermatol* 2012; 5:33–43.
  22. Shahi V, Wetter DA, Howe BM, et al. Plain radiography is effective for the detection of calcinosis cutis occurring in association with autoimmune connective tissue disease. *Br J Dermatol* 2014; 170:1073–1079.
  23. Valenzuela A, Chung L. Calcinosis. In: Varga J, Denton C, Wigley F, et al., editors. *Scleroderma*. Cham: Springer; 2017.
  24. Chung L, Valenzuela A, Fiorentino D, et al. Validation of a novel radiographic scoring system for calcinosis affecting the hands of patients with systemic sclerosis. *Arthritis Care Res (Hoboken)* 2015; 67:425–430.
  25. Freire V, Bazeli R, Elhai M, et al. Hand and wrist involvement in systemic sclerosis: US features. *Radiology* 2013; 269:824–830.
  26. Elhai M, Guerini H, Bazeli R, et al. Ultrasonographic hand features in systemic sclerosis and correlates with clinical, biologic, and radiographic findings. *Arthritis Care Res (Hoboken)* 2012; 64:1244–1249.
  27. Suliman YA, Kafaja S, Fitzgerald J, et al. Ultrasound characterization of cutaneous ulcers in systemic sclerosis. *Clin Rheumatol* 2018; 37: 1555–1561.
  28. Pracon G, Plaza M, Walentowska-Janowicz M, Sudol-Szopinska I. The value of ultrasound in the diagnosis of limited scleroderma – a case report. *J Ultrason* 2015; 15:326–331.
  29. Freire V, Becce F, Feydy A, et al. MDCT imaging of calcinosis in systemic sclerosis. *Clin Radiol* 2013; 68:302–309.
  30. Hsu V, Bramwit M, Schlesinger N. Use of dual-energy computed tomography for the evaluation of calcinosis in patients with systemic sclerosis. *Clin Radiol* 2015; 34:1557–1561.
  31. Kimball AB, Summers RM, Turner M, et al. Magnetic resonance imaging detection of occult skin and subcutaneous abnormalities in juvenile dermatomyositis. Implications for diagnosis and therapy. *Arthritis Rheum* 2000; 43:1866–1873.
  32. Shimizu M, Ueno K, Ishikawa S, et al. Role of activated macrophage and inflammatory cytokines in the development of calcinosis in juvenile dermatomyositis. *Rheumatology (Oxford)* 2014; 53:766–767.
  33. Davies CA, Jeziorska M, Freemont AJ, Herrick AL. The differential expression of VEGF, VEGFR-2, and GLUT-1 proteins in disease subtypes of systemic sclerosis. *Hum Pathol* 2006; 37:190–197.
  34. Luders S, Friedrich S, Ohndorf S, et al. Detection of severe digital vasculopathy in systemic sclerosis by colour Doppler sonography is associated with digital ulcers. *Rheumatology (Oxford)* 2017; 56:1865–1873.
  35. Park JK, Fava A, Carrino J, et al. Association of acroosteolysis with enhanced osteoclastogenesis and higher blood levels of vascular endothelial growth factor in systemic sclerosis. *Arthritis Rheumatol* 2016; 68:201–209.
- This study analyzed peripheral blood mononuclear cells (PBMCs) from 26 SSc patients (11 with acro-osteolysis and 15 without acro-osteolysis) and 14 healthy controls, and found increased osteoclast formation and higher VEGF levels in SSc patients with acro-osteolysis as compared with SSc patients without acro-osteolysis and healthy controls. The majority of SSc patients with acro-osteolysis also had calcinosis.
36. Omair MA, Pagnoux C, McDonald-Blumer H, Johnson SR. Low bone density in systemic sclerosis. A systematic review. *J Rheumatol* 2013; 40: 1881–1890.
  37. Gauhar R, Wilkinson J, Harris J, et al. Calcinosis preferentially affects the thumb compared to other fingers in patients with systemic sclerosis. *Scand J Rheumatol* 2016; 45:317–320.
- This study shows hand radiographs of 68 SSc patients demonstrating that the thumbs, followed by the index finger, are more commonly affected by calcinosis than other digits, providing insight into the role of repetitive trauma in the pathogenesis of SSc-related calcinosis.
38. Asano Y, Sato S. Vasculopathy in scleroderma. *Semin Immunopathol* 2015; 37:489–500.
  39. Cantatore FP, Maruotti N, Corrado A, Ribatti D. Angiogenesis dysregulation in the pathogenesis of systemic sclerosis. *Biomed Res Int* 2017; 2017: 5345673.
- This review article is focused on current knowledge on the mechanisms responsible for angiogenesis dysregulation in systemic sclerosis.
40. Davies CA, Jeziorska M, Freemont AJ, Herrick AL. Expression of osteonectin and matrix GLA protein in scleroderma patients with and without calcinosis. *Rheumatology (Oxford)* 2006; 45:1349–1355.
  41. Dhore CR, Cleutjens JP, Lutgens E, et al. Differential expression of bone matrix regulatory proteins in human atherosclerotic plaques. *Arterioscler Thromb Vasc Biol* 2001; 21:1998–2003.
  42. Zeboudj AF, Shin V, Bostrom K. Matrix GLA protein and BMP-2 regulate osteoinduction in calcifying vascular cells. *J Cell Biochem* 2003; 90: 756–765.



43. Spronk HM, Soute BA, Schurgers LJ, *et al.* Matrix GLA protein accumulates at the border of regions of calcification and normal tissue in the media of the arterial vessel wall. *Biochem Biophys Res Commun* 2001; 289:485–490.
44. Wallin R, Wajih N, Greenwood GT, Sane DC. Arterial calcification: a review of mechanisms, animal models, and the prospects for therapy. *Med Res Rev* 2001; 21:274–301.
45. Ughi N, Crotti C, Ingegnoli F. Effectiveness and safety of oxycodone/naloxone in the management of chronic pain in patients with systemic sclerosis with recurrent digital ulcers: two case reports. *Clin Interv Aging* 2016; 11:307–311.
46. Netsch D. Calcinosis cutis: WOC nurse management. *J Wound Ostomy Continence Nurs* 2018; 45:83–86.
47. Daoussis D, Antonopoulos I, Liossis SN, *et al.* Treatment of systemic sclerosis-associated calcinosis: a case report of rituximab-induced regression of CREST-related calcinosis and review of the literature. *Semin Arthritis Rheum* 2012; 41:822–829.
48. Palmieri GM, Sebes JI, Aelion JA, *et al.* Treatment of calcinosis with diltiazem. *Arthritis Rheum* 1995; 38:1646–1654.
49. Dolan AL, Kassimos D, Gibson T, Kingsley GH. Diltiazem induces remission of calcinosis in scleroderma. *Br J Rheumatol* 1995; 34:576–578.
50. Farah MJ, Palmieri GM, Sebes JI, *et al.* The effect of diltiazem on calcinosis in a patient with the CREST syndrome. *Arthritis Rheum* 1990; 33:1287–1293.
51. Balin SJ, Wetter DA, Andersen LK, Davis MD. Calcinosis cutis occurring in association with autoimmune connective tissue disease: the Mayo Clinic experience with 78 patients, 1996–2009. *Arch Dermatol* 2012; 148: 455–462.
52. Li G, Adachi JD, Cheng J, *et al.* Relationship between calcium channel blockers and skin fibrosis in patients with systemic sclerosis. *Clin Exp Rheumatol* 2017; 106:56–60.
- Study of 5-year follow-up data from the Canadian Scleroderma Research Group registry to assess the relationship between use of calcium channel blockers and clinical features of SSc, including calcinosis.
53. Dima A, Balanescu P, Baicus C. Pharmacological treatment in calcinosis cutis associated with connective-tissue diseases. *Rom J Intern Med* 2014; 52:55–67.
54. Marco Puche A, Calvo Penades I, Lopez Montesinos B. Effectiveness of the treatment with intravenous pamidronate in calcinosis in juvenile dermatomyositis. *Rom J Intern Med* 2010; 28:135–140.
55. Slimani S, Abdessemed A, Haddouche A, Ladjouze-Rezig A. Complete resolution of universal calcinosis in a patient with juvenile dermatomyositis using pamidronate. *Joint Bone Spine* 2010; 77:70–72.
56. Palaniappan P, Lionel AP, Kumar S. Successful treatment of calcinosis cutis in juvenile dermatomyositis with pamidronate. *J Clin Rheumatol* 2014; 20:454–455.
57. Canas CA, Bonilla-Abadia F, Mejia M, Tobon GJ. Recovery of severe muscular and fascial calcinosis after treatment with bisphosphonates in a child with juvenile dermatomyositis. *J Clin Rheumatol* 2015; 21:267–269.
58. Saini I, Kalaivani M, Kabra SK. Calcinosis in juvenile dermatomyositis: frequency, risk factors and outcome. *Rheumatol Int* 2016; 36:961–965.
59. Fujii N, Hamano T, Isaka Y, *et al.* Risedronate: a possible treatment for extraosseous calcification. *Clin Calcium* 2005; 15(Suppl 1):75–78.
60. Cukierman T, Elinav E, Korem M, Chajek-Shaul T. Low dose warfarin treatment for calcinosis in patients with systemic sclerosis. *Ann Rheum Dis* 2004; 63:1341–1343.
61. Lassoued K, Saïag P, Anglade MC, *et al.* Failure of warfarin in treatment of calcinosis universalis. *Am J Med* 1988; 84:795–796.
62. Palaniswamy C, Sekhri A, Aronow WS, *et al.* Association of warfarin use with valvular and vascular calcification: a review. *Clin Cardiol* 2011; 34:74–81.
63. Nigwekar SU, Kroshinsky D, Nazarian RM, *et al.* Calciphylaxis: risk factors, diagnosis, and treatment. *Am J Kidney Dis* 2015; 66:133–146.
64. Bair B, Fivenson D. A novel treatment for ulcerative calcinosis cutis. *J Drugs Dermatol* 2011; 10:1042–1044.
65. Barrio-Diaz P, Moll-Manzur C, Álvarez-Velz S, Vera-Kellet C. Topical sodium metabisulfite for the treatment of calcinosis cutis: a promising new therapy. *Br J Dermatol* 2016; 175:608–611.
66. Goossens J, Courbebaisse M, Caudron E, *et al.* Efficacy of intralesional sodium thiosulfate injections for disabling tumoral calcinosis: two cases. *Semin Arthritis Rheum* 2017; 47:451–455.
67. Baumgartner-Nielsen J, Olesen AB. Treatment of skin calcifications with intralesional injection of sodium thiosulphate: a case series. *Acta Derm Venereol* 2016; 96:257–258.
68. Song P, Fett NM, Lin J, *et al.* Lack of response to intravenous sodium thiosulfate in three cases of extensive connective tissue disease-associated calcinosis cutis. *Br J Dermatol* 2017; 176:1412–1415.
69. Mageau A, Guignon V, Ratzimbasafy V, *et al.* Intravenous sodium thiosulfate for treating tumoral calcinosis associated with systemic disorders: report of four cases. *Joint Bone Spine* 2017; 84:341–344.
70. Tosounidou S, MacDonald H, Situnayake D. Successful treatment of calcinosis with infliximab in a patient with systemic sclerosis/myositis overlap syndrome. *Rheumatology (Oxford)* 2014; 53:960–961.
71. de Paula DR, Klem FB, Lorencetti PG, *et al.* Rituximab-induced regression of CREST-related calcinosis. *Clin Rheumatol* 2013; 32:281–283.
72. Giuggioli D, Lumetti F, Colaci M, *et al.* Rituximab in the treatment of patients with systemic sclerosis. Our experience and review of the literature. *Autoimmun Rev* 2015; 14:1072–1078.
73. Hurabielle C, Allanore Y, Kahan A, Avouac J. Flare of calcinosis despite rituximab therapy. *Semin Arthritis Rheum* 2014; 44:e5–e6.
74. Dubos M, Ly K, Martel C, Fauchais AL. Is rituximab an effective treatment of refractory calcinosis? *BMJ Case Rep* 2016; pii:bcr2015213179.
75. Robertson LP, Marshall RW, Hickling P. Treatment of cutaneous calcinosis in limited systemic sclerosis with minocycline. *Ann Rheum Dis* 2003; 62:267–269.
76. Reiter N, El-Shabrawi L, Leinweber B, Aberer E. Subcutaneous morphea with dystrophic calcification with response to ceftriaxone treatment. *Ann Rheum Dis* 2010; 63:e53–e55.
77. Hudson PM, Jones PE, Robinson TW, Dent CE. Extensive calcinosis with minimal scleroderma: treatment of ectopic calcification with aluminum hydroxide. *Proc R Soc Med* 1974; 67:1166–1168.
78. Hazen PG, Walker AE, Carney JF, Stewart JJ. Cutaneous calcinosis of scleroderma. Successful treatment with intralesional adrenal steroids. *Arch Dermatol* 1982; 118:366–367.
79. Fuchs D, Fruchter L, Fishel B, *et al.* Colchicine suppression of local inflammation due to calcinosis in dermatomyositis and progressive systemic sclerosis. *Clin Rheumatol* 1986; 5:527–530.
80. Vereecken P, Stallenberg B, Tas S, *et al.* Ulcerated dystrophic calcinosis cutis secondary to localised linear scleroderma. *Int J Clin Pract* 1998; 52:593–594.
81. Schanz S, Ulmer A, Fierlbeck G. Response of dystrophic calcification to intravenous immunoglobulin. *Arch Dermatol* 2008; 144:585–587.
82. Sultan-Bichat N, Menard J, Perceau G, *et al.* Treatment of calcinosis cutis by extracorporeal shock-wave lithotripsy. *J Am Acad Dermatol* 2012; 66: 424–429.
83. Blumhardt S, Frey DP, Toniolo M, *et al.* Safety and efficacy of extracorporeal shock wave therapy (ESWT) in calcinosis cutis associated with systemic sclerosis. *Clin Exp Rheumatol* 2016; 100:177–180.
84. Bottomley WW, Goodfield MJ, Sheehan-Dare RA. Digital calcification in systemic sclerosis: effective treatment with good tissue preservation using the carbon dioxide laser. *Br J Dermatol* 1996; 135:302–304.
85. Chamberlain AJ, Walker NP. Successful palliation and significant remission of cutaneous calcinosis in CREST syndrome with carbon dioxide laser. *Dermatol Surg* 2003; 29:968–970.
86. Merlino G, Germano S, Carlucci S. Surgical management of digital calcinosis in CREST syndrome. *Aesthetic Plast Surg* 2013; 37:1214–1219.
87. Fujimoto M, Asano Y, Ishii T, *et al.* The wound/burn guidelines - 4: guidelines for the management of skin ulcers associated with connective tissue disease/vasculitis. *J Dermatol* 2016; 43:729–757.
- Japanese Dermatological Association guidelines on the treatment of skin ulcers and calcinosis associated with connective tissue diseases, providing a good review of available diagnostic and therapeutic approaches.
88. Sadding N, Miller JJ, Miller OF 3rd, Clarke JT. Surgical debridement of painful fingertip calcinosis cutis in CREST syndrome. *Arch Dermatol* 2009; 145:212–213.
89. Lapner MA, Goetz TJ. High-speed burr debulking of digital calcinosis cutis in scleroderma patients. *J Hand Surg Am* 2014; 39:503–510.