

REVIEW

Editorial Process: Submission:07/30/2017 Acceptance:05/03/2018

Oral Lichen Planus: an Overview of Potential Risk Factors, Biomarkers and Treatments

Tahereh Nosratzahi*

Abstract

Oral lichen planus (OLP) is an immune-related disorder with unknown exact etiology but established prevalence in females. There are six clinical forms of OLP, ranging from asymptomatic white keratotic lesions to painful erosions and ulcerations. The aim of the present report is to overview pathologic and therapeutic aspects. Peroxidation products, antioxidants, cortisol, and immunoglobulins are potential biomarkers to predict OLP occurrence. The risk of OLP development in patients with hepatitis B and C infection is 2-fold greater than in healthy individuals, while there is no significant relation with diabetes mellitus. Corticosteroids are common drugs to treat OLP and their combination with other agents can be most effective. Folic acid and variants of vitamin B are also potential treatments since they target hematological abnormalities.

Keywords: Lichen Planus- oral- diagnosis- hepatitis- therapeutics- vitamins

Asian Pac J Cancer Prev, **19** (5), 1161-1167

Introduction

Oral lichen planus (OLP) is a chronic disorder with the primary role of immune system (Eisen et al., 2005). Since OLP is an immune-related disorder, stress and anxiety and other factors in relation with immune system can be causative factors which probably trigger to this disease (Vincent et al., 1990). This disease dominantly occurs among women and involves 2-5% of the general population. Also, its possible onset is in the decade 4-5 of life (Burket et al., 2008). The exact etiology of OLP has not been discovered, and it is mostly considered as a multifactorial process with different triggers such as mechanical, electrochemical, trauma and psychological, infectious, malnutrition, stress, overworking, mucous exciting factors and allergy, endocrine disorders, salivary gland disorders, genetic susceptibility and immunological illnesses (Nielsen et al., 1997; Torrente-Castells et al., 2010; Bombeccari et al., 2011).

Hydropic degeneration of the basal epithelial cells (keratinocytes), an intraepithelial and dense subepithelial lymphocytic infiltration of mononuclear cells and epithelial invasion are histological characteristics of OLP (Khan et al., 2003; Shen et al., 2012). Presence of initial precursors are primary causatives for developing oral cancer (Ansar et al., 2011a) that oral leukoplakia and submucous fibrosis are two major precancerous lesions among them, which 8-10% of these lesions become finally malignant (Ansar et al., 2011a) The World Health Organization (WHO) classified OLP as a potential

pre-malignant lesion (van der Meij and van der Waal, 2003) indicating its potentiality to convert into squamous cell carcinoma (Shen et al., 2012).

Previous study showed OLP occurrence through both of antigen-specific and non-specific mechanisms. In antigen-specific mechanisms, basal keratinocytes present antigen and antigen-specific keratinocyte are killed by CD8+ cytotoxic T lymphocytes. In non-specific mechanisms, mast cell degranulates and matrix metalloproteinase activates in OLP lesions (Sugerman et al., 2002). OLP is a T-cell mediated inflammatory disease (Ishii, 1987; Hirota et al., 1990). Through mast cell/T-cell interactions in OLP lesions, mast cell released cytokines, chemokines and matrix metalloproteinases can promote T-cell activation, migration, proliferation and differentiation (Zhao et al., 2002).

The clinical presentation of OLP involves a ranges from asymptomatic white keratotic lesions to painful erosions and ulcerations (Pakfetrat et al., 2009) with six distinctive clinical forms: Keratotic reticular, papular, plaque-like white patches, erosive, atrophic, and bullous (ulcerative) (Shen et al., 2012). The epidemiologic distribution of lesions differs in each geographical region, as the majority of the lesions in Iran were reported reticular (66%) (Nosratzahi et al., 2016), but generally, the most common are reticular and erosive form. (Oliveira Alves et al., 2010) The first three types are often present minor or no symptoms without any complaints that is, painless, (Radwan-Oczko and Kozłowski, 2011) with no need for any intervention or treatment, but patients

should be checked on regularly with a recommended follow-up visits every 4–6 months or sooner if any symptoms occur (Sugerman et al., 2002; Kaplan et al., 2012). On the other hand, the erosive, atrophic, and ulcerative lesions, that are surrounded by keratotic forms suggest a damaged epithelium, a painful and/or a burning sensation at the oral mucosa, and thus interfere with eating, speaking, and swallowing. Oral pain resulting from OLP may be ranged from a little bothersome to annoying pain that can inhibit patients from their daily function (Thongprasom et al., 2007). It can remain in some patients for a long time, but a spontaneous resolution of the atrophic lesions is sometimes observed (Radwan-Oczko and Kozłowski, 2011).

Many studies have been done, focusing on OLP with different point of views; pathologically and therapeutically. In the present study, we tried to overview both pathologic and therapeutic achievements in this issue regarding the significance of biomarkers for OLP diagnosis, OLP relation with other diseases, and more effective treatments on OLP.

Materials and Methods

Data were collected from the following data bases: Pubmed, google scholar, and ISI web of knowledge. The keywords which were used to search are including “Oral lichen planus”, “biomarkers”, “treatments”, and “high risk patients”. The articles were published from 1980 until 2016. 83 articles were evaluated.

Diagnosis

Up to now, diagnosis of malignant transformation have been performed with biopsies, especially based on epithelial dysplasia, which is not always reliable; thus, developing new predicting methods to diagnose malignant potential of lesions have recognized to be necessary (Allison et al., 1998). Meanwhile, recognition of new biomarkers seems to be non-invasive as well as a fast method to diagnose disease in initial steps. For instance, low salivary peroxidation products has been reported in oral cancer and OLP (Rai et al., 2006; Shirzad et al., 2014). On the other hand, decrease in antioxidant activity in cancer has been reported (Halliwell, 2012) besides the studies that have shown supplementation of antioxidants such as vitamin C and E are beneficial to prevent cancer (Dormandy, 1983; Halliwell, 1996). Following, we would review some potential biomarkers which are suitable to diagnose OLP (Table 1).

Antioxidant and peroxidation level

It has been shown that in patient with OLP the salivary level of peroxidation products such as malonaldehyde (MDA) and 8-hydroxydeoxyguanosine (8-OHdG) increased and that of antioxidants such as vitamin C and E decreased compared with control healthy individuals. After treatment with curcumin, for more than two hundred days, the level of peroxidation products (oxidants) decreased and that of antioxidants increased. Thus, level of vitamin C and E, as antioxidants, might be a suitable biomarkers to predict precancerous conditions like OLP

(Rai et al., 2010).

Moreover, Studies have demonstrated the presence of serum anti-gastric parietal cell autoantibody (GPCA) in several different groups of OLP patients (Chang et al., 2009). Group of GPCA-positive OLP has signs and symptoms of oral lichen planus in forms of reticular, erosive or ulcerative oral mucosal lesions and pain or burning sensation of lesional oral mucosa. Also, Treatment of OLP patients with levamisole plus vitamin B12 showed a significant decrease in GPCA level (Lin et al., 2011). This reduction in GPCA level was consonant with improvement of buccal mucosa lesions. As a result, GPCA level of serum is a potential biomarker to diagnose oral lesion planus.

Cortisol

In a study, the salivary cortisol are found to be correlated with the incidence of OLP, and one might consider the cortisol levels of salivary as a potential indicator in the development or creation of OLP lesions (Rabiei et al., 2012). Girardi et al., (2011) studied the levels of salivary cortisol, dehydroepiandrosterone (DHEA), and psychological factors in patients with OLP. In that study, 31 patients with OLP were matched with same number of healthy individuals in terms of age and sex. The Beck test was used to measure the level of anxiety and depression in patients. They observed no significant difference between salivary cortisol level in OLP group and control group. In another study, Ghalyani and Tavangar, (2010) found lesser salivary cortisol level in patients with lichen planus than those non-infected individuals. Also, it has been found that cortisol level in patients with OLP was significantly lower than control group. In addition, SCL-90 questionnaire results showed that the anxiety and depression was higher in these patients. As a conclusion, despite of some controversies in correlation between cortisol and OLP, since cortisol leads to a reduction in the number of lymphocytes and other immune cells, any dysfunction in the HPA (Hypothalamic– pituitary–adrenal axis) in patients with anxiety and depression leads to reduction in blood and salivary cortisol secretion, and cause diseases affecting the immune system like lichen planus (Nosratzehi et al., 2014).

Immunoglobulin

Sistig et al., (2002) studied patients with lichen planus and reported increased levels of IgG and IgA among them. Ghalayani et al., (2009) evaluated the level of IgA and IgG in patients with OLP and lichenoid reaction Lesions. The results showed higher level of IgA and IgG in patients than normal individuals in both groups. An increase in the salivary IgA level was observed in patients with oral leukoplakia, OLP and carcinoma of the oral cavity (Sato, 1991; Sistig et al., 2002). Also, in a study conducted with us, IgA level in patients with OLP was higher than healthy individuals, although this difference was not significant (Nosratzehi et al., 2014).

Overlap with other diseases

Since OLP is an immune deficiency disease, it might relate with incidence of other disease. Diabetes mellitus

and hepatitis are liver dysfunctions with immune system disorders, and has been considered as potential disease which might enhance the risk of OLP occurrence (Figure 1).

Diabetes mellitus

According to reports, diabetes mellitus is associated with oral lichen planus in 14–85% of the cases (Seyhan et al., 2007; Atefi et al., 2012). The autoimmune background of lichen planus could be a speculation for diabetes mellitus occurrence, due to the same pathogenesis of both diseases (Romero et al., 2002). Ahmed et al., (2012) concluded that OLP has a significant relationship with non-insulin-dependent diabetes mellitus compared with the normal population. In another study, Bagewadi and Bhoweer, (2011) argued that diabetes mellitus and hypertension play no direct relation with the etiology of oral lichen planus. Prevalence of diabetes mellitus among OLP patients, in different populations, has been reported very different during last decade (Seyhan et al., 2007; Ara et al., 2011; Atefi et al., 2012). However, other studies has revealed that there was no positive dependency between diabetes mellitus and oral lichen planus (Saini et al., 2010; Ansar et al., 2011a; Bagewadi and Bhoweer, 2011). We performed a study on 50 patient, and it was observed that fasting blood glucose and HbA1C levels in patient with OLP did not differ significantly with healthy individuals (Nosratzahi et al., 2015).

Hepatitis

OLP is known to be related to chronic liver diseases, although its relationship with HCV infection is a controversial issue, seeming to be proven in some geographic areas including Japan and Southern Europe (Pilli et al., 2002). It has shown that the risk of developing lichen planus in patients who are positive for hepatitis B surface antigen (HBsAg) are twice greater than HBsAg-negative patients. Furthermore, after administration of different HBV vaccines, anti-HBV antibodies were seen in lichen planus patients of lichenoid eruption (Jayavelu and Sambandan, 2012). Hepatitis C virus (HCV) is one of the main reason of chronic hepatic disease throughout the world (Gheorghe et al., 2014). It was shown that in comparison to general population, the risk of developing LP in patients infected with HCV are twice. The reports associating LP with HCV disclose obvious geographic difference (Gheorghe et al., 2014). The relationship are stronger in Japanese and Mediterranean population, possibly because of higher incidence of HCV infections (Glick, 2015). A study in Iran on 134 patients showed that 2.23% of patients with OLP were positive for HCV antibody (Gerayli et al., 2015). Also, similar studies in other countries in this region have reported similar findings. Studies in Pakistan (Mahboob et al., 2003) and Saudi Arabia (Asaad and Samdani, 2005) too, have reported a relationship between LP and hepatitis C; however, a study in Turkey did not report such a relationship (Karavelioglu et al., 2004). Studies in other regions of the world, also, have shown no relation between HCV and OLP (Luis-Montoya et al., 2005; de Mattos Camargo Grossmann et al., 2007).

The incidence of hepatitis C in LP patients has been reported to be highly variable in different countries, ranging from 8.3% in France to 62% in Japan. Many studies have shown that 2.4–8% of patients who suffer from chronic hepatic diseases (associated with hepatitis C) have LP, too (16; 15; 14) with different infection rates in different countries (Denli et al., 2004; Lodi et al., 2010; Jayavelu and Sambandan, 2012; Nagao and Sata, 2012). Many studies have revealed the epidemiological and genotypic data on hepatitis C virus in Iran, representing that 1a, 3a and 1b were the most dominant genotypes in Shiraz city, while there was a high occurrence of HCV infection in hemophilic patients in Isfahan city (MaziarMojtabavi et al., 2007; Alavian et al., 2012; Jamalidoust et al., 2014). Two studies in Kerman (Rahnama et al., 2005) and Hamadan (Ansar et al., 2011b) showed no association between LP and hepatitis C. Another study in Shiraz showed no relation between HCV infection and OLP (Ghodsi et al., 2004).

The result of independent T-test showed no significant relation between HBV and HCV infection and the presence of OLP ($P > 0.05$). Relationship between LP and HCV might be attributed to heterogeneity. Differences in genetic factors, including differences in human leukocyte antigen types, in different geographical locations, (Carrozzo et al., 2004). Different reasons have been suggested for these variations based on the geographic area, including the occurrence of HBV and HCV, the incidence of other etiologic factors for OLP, alterations in genetic susceptibility to HCV-induced OLP, diversities in the genotypes of HCV and cytotoxic reactions to keratinocytes expressing HBsAg (Nosratzahi et al., 2016).

Treatment

Up to now, various topically treatments including: Corticosteroids, immunosuppressants such as cyclosporin, tacrolimus, and retinoids have been tried to relieve OLP (Arbabi-Kalati et al., 2014). The most commonly used drugs are Corticosteroids, but other drugs such as azathioprine, calcineurin inhibitors, mycophenolate mofetil, dapsone, retinoids, and hydroxychloroquine can be used in recalcitrant cases (Lavanya et al., 2011).

Moreover, it is assumed that markers of oxidative stress are associated with different local oral conditions. The antioxidants' level is a potential determinant of susceptibility to be affected by OLP. This results suggest that oxidative stress can be the major trigger for OLP (Yang et al., 2006; Azizi and Farshchi, 2012). Thus, antioxidants such as vitamins has been widely used, because vitamin A and E inhibits the lipid peroxidation of cell membrane, whereas vitamin C plays as a cofactor for many enzymes with collagen structure stabilization role and also help Vitamin E reproduction (Keller and Fenske, 1998). Curcumin, also, is an antioxidant that has been used as chemopreventive agent in various types of cancer, as well as in inhibition of viral and bacterial growth (Aggarwal et al., 2003). Also, curcumin increased the both salivary and serum level of vitamin A, E and C through activation of mitochondrial enzymes (Krishnaswamy et al., 1995; Atsumi et al., 2005; Rai et al., 2010). Following, these two types of treatment has been widely reviewed.

Table 1. Potential Biomarkers to Diagnose Oral Lichen Planus

Potential biomarker	Level in OLP patients
Peroxidation products	Increase
Antioxidants (vitamin C and E)	Decrease
GPCA	Increase
Cortisol	Decrease
Immunoglobulin	Increase

OLP, Oral lichen planus; GPCA, anti-gastric parietal cell autoantibody

Corticosteroid

Corticosteroids are well-documented anti-inflammatory and anti-immune effects. Glucocorticoids, as a class of corticosteroids, suppress the inflammatory response by inhibiting synthesis of the two main inflammatory products, leukotrienes and prostaglandins (Goppelt-Struebe et al., 1989). Also, glucocorticoids suppress cell-mediated immunity (Leung and Bloom, 2003). Since OLP is a cell-mediated chronic inflammatory oral disease and corticosteroids have both anti-T cell-mediated and anti-inflammatory immune functions, administration of corticosteroid can result in the accelerated healing OLP patients (Kuo et al., 2013). Corticosteroids have been used topically as the first-line drugs, while they are usually reserved systemically for widespread erosive OLP or acute exacerbation (Sugerman et al., 2002; Roopashree et al., 2010). In a study, triamcinolone acetonide was injected locally to 50 erosive OLP patients and low- or medium-dose of prednisolone, a synthetic glucocorticoid was administered orally for 2 weeks to achieve a high and relatively long-lasting local corticosteroid level in a short period of time, and obtained a 90% complete response rate (Kuo et al., 2013). In another study, the topical 0.1% dexamethasone has been used for 6 weeks on only thirteen patients. The levels of all investigated cytokines, after treatment period, were significantly decreased and the subjects' symptoms were decreased in a significant way (Rhodus et al., 2006).

Also, combination of corticosteroids with other compounds has been used to reinforce its therapeutic effect. Combination of selenium with topical corticosteroids plus the antifungal agent, for instance, showed effective improvement of healing of Oral lichen planus lesion size and pain sensation compared with corticosteroids only. Although selenium is not itself an antioxidant, it is considered an essential component of the endogenous

antioxidant enzyme that is called glutathione peroxidase (GSH-Px) (Canter et al., 2007). Licorice, another additive compound, is a plant with very anti-inflammatory effects which its anti-inflammatory mechanism includes inhibition of glucocorticoid metabolism and complement (Arbabi-Kalati et al., 2014). In a study on 40 patients divided in two groups, first group received bioadhesive paste containing 5% of licorice extract and second group were treated by bioadhesive paste with synthetic corticosteroid, triamcinolone, 0.1% which was similar in shape, taste and color. Although there was no statistical significance between mean of pain, clinical improvement in first group was more than group treated with corticosteroid only (Arbabi-Kalati et al., 2014).

Vitamin B

Hematological abnormalities, including deficiency or marginally low levels of vitamins B1, B6, B12, iron and folate have been widely observed in OLP patients (Challacombe, 1986). In a study, conducted on 352 OLP patients, the high blood homocysteine level in OLP patients attributed to deficiencies in folic acid and vitamins B12 and B6, and found a close relation of high blood homocysteine level to severity of OLP (Chen et al., 2015). They suggested that the supplementation of hematins or multiple B vitamins including B1, B2, B6, and B12 may be beneficial for this specific group of OLP patients.

Moreover, in another study including 147 GPCA-positive OLP patients, treatment with levamisole plus vitamin B12 effectively reduced the high serum GPCA level to undetectable one and resulted in a significant improvement in oral signs and symptoms of OLP (Lin et al., 2011). It has been shown that treatment of levamisole for a period of approximately 7 months can significantly reduce the abnormally high serum IL-6, IL-8, and TNF- α levels to normal and subsequently with a significant improvement in oral symptoms and signs in patients with OLP (Sun et al., 2005; Sun et al., 2007). Reduction in the number and size of oral lesions can be attributed to a significant decrease in the release of basal cell and nuclear autoantigens and a significant diminution of oral inflammation. However, treatment with levamisole only did not drop the serum GPCA amount to a significantly lower level and did not improve oral signs and symptoms of pernicious anemia in OLP patients; which showed it may not be effective enough to promote the healing of autoimmune atrophic gastritis, and resulted in the continuous release of parietal cell autoantigens and persistent formation of GPCA in local tissues and blood circulation (Chang et al., 2009). This results indicated to the significant role of vitamin B12 in healing of OLP.

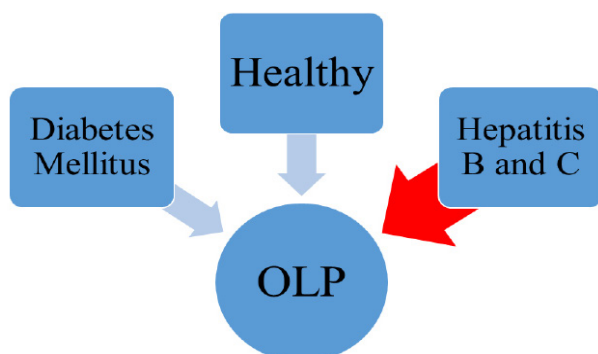


Figure 1. Risk of OLP Development in Hepatitis Patients are more than Healthy Individuals and Diabetic Patients.

In conclusion, oral lichen planus is an immune disorder disease which produces precancerous lesions. Thus, new recognition procedures despite of conventional biopsy methods seems to be necessary. Oxidants and antioxidants level is one of the potential biomarkers to diagnose OLP. Increase in oxidants and decrease in antioxidants level might be indication of OLP occurrence. In addition, increase of serum GPCA and immunoglobulins like IgA and IgG, and decrease of cortisol are other potential biomarkers to predict OLP. These biomarkers are measurable in both serum and salivary fluids which make it possible to diagnose OLP non-invasively. Moreover, no significant relation was found between OLP and diabetes mellitus while both of these diseases are autoimmune disorders. On the other hand, the risk of developing lichen planus is 2-fold greater in patients infected by HBV or HCV than non-infected individuals, however this probable risk varies in different geographical regions. Finally, corticosteroids are the common drugs to treat OLP which usually have been used topically. Combination of corticosteroids with other compounds like cofactors can increase their curing strength. Also, hematological abnormalities, like vitamin B and folate deficiencies, have been observed in OLP patients. Compensation of these deficiencies with variants of vitamin B and folic acid, even in combination with other drugs, have shown therapeutic effects on OLP patients.

References

- Aggarwal BB, Kumar A, Bharti AC (2003). Anticancer potential of curcumin: preclinical and clinical studies. *Anticancer Res*, **23**, 363-98.
- Ahmed I, Nasreen S, Jehangir U, et al (2012). Frequency of oral lichen planus in patients with noninsulin dependent diabetes mellitus. *J Pak Assoc Dermatol*, **22**, 30-4.
- Alavian SM, Jabbari H, Daryani NE (2012). Hepatitis C virus: the rising concerns and growing hopes, report from the HCV symposium, fourth Tehran hepatitis congress, November 2011, Tehran, Iran. *Hepat Mon*, **12**, 423.
- Allison P, Locker D, Feine JS (1998). The role of diagnostic delays in the prognosis of oral cancer: a review of the literature. *Oral Oncol*, **34**, 161-70.
- Ansar A, Farshchian M, Ghasemzadeh SM (2011a). Comparison of the frequency of diabetes mellitus in the patients with lichen planus and normal controls: A case-control study. *J Cosmet Dermatol*, **2**, 78-84.
- Ansar A, Zamanian A, Farschian M, et al (2011b). Comparison of seropositivity of HCV between oral lichen planus and healthy control group in Hamedan province (west of Iran). *Our Dermatol Online*, **2**, 181.
- Ara SA, Mamatha GP, Rao BB (2011). Incidence of diabetes mellitus in patients with lichenplanus. *Int J Dent Clin*, **3**, 147-52.
- Arbabi-Kalati F, Nosratzahi T, Hamishehkar H, et al (2014). Comparison of effectiveness of the bioadhesive pastes containing licorice 5% and topical corticosteroid for the treatment of oral lichen planus: A pilot study. *ZJRMS*, **16**, 7-9.
- Asaad T, Samdani AJ (2005). Association of lichen planus with hepatitis C virus infection. *Ann Saudi Med*, **25**, 243-6.
- Atefi N, Majedi M, Peyghambari S, et al (2012). Prevalence of diabetes mellitus and impaired fasting blood glucose in patients with Lichen Planus. *Med J Islam Repub Iran*, **26**, 22-6.
- Atsumi T, Fujisawa S, Tonosaki K (2005). Relationship between intracellular ROS production and membrane mobility in curcumin- and tetrahydrocurcumin-treated human gingival fibroblasts and human submandibular gland carcinoma cells. *Oral Dis*, **11**, 236-42.
- Azizi A, Farshchi F (2012). Comparison of salivary and plasma antioxidant levels in lichen planus patients and healthy subjects. *J Oral Pathol Med*, **41**, 524-6.
- Bagewadi A, Bhoweer AK (2011). Oral lichen planus and its association with diabetes mellitus and hypertension. *Indian Acad Oral Med Radiol*, **23**, 300.
- Bombeccari GP, Guzzi G, Tettamanti M, et al (2011). Oral lichen planus and malignant transformation: a longitudinal cohort study. *Oral Surg Oral Med Oral Pathol Oral Radiol Endod*, **112**, 328-34.
- Burket LW, Greenberg MS, Glick M, et al 2008. *Burket's Oral Medicine*, Hamilton, BC Decker.
- Canter PH, Wider B, Ernst E (2007). The antioxidant vitamins A, C, E and selenium in the treatment of arthritis: a systematic review of randomized clinical trials. *Rheumatology (Oxford)*, **46**, 1223-33.
- Carrozzo M, Uboldi de Capei M, Dametto E, et al (2004). Tumor necrosis factor-alpha and interferon-gamma polymorphisms contribute to susceptibility to oral lichen planus. *J Invest Dermatol*, **122**, 87-94.
- Challacombe SJ (1986). Haematological abnormalities in oral lichen planus, candidiasis, leukoplakia and non-specific stomatitis. *Int J Oral Maxillofac Surg*, **15**, 72-80.
- Chang JY, Chiang CP, Hsiao CK, et al (2009). Significantly higher frequencies of presence of serum autoantibodies in Chinese patients with oral lichen planus. *J Oral Pathol Med*, **38**, 48-54.
- Chen HM, Wang YP, Chang JY, et al (2015). Significant association of deficiencies of hemoglobin, iron, folic acid, and vitamin B12 and high homocysteine level with oral lichen planus. *J Formos Med Assoc*, **114**, 124-9.
- de Mattos Camargo Grossmann S, de Aguiar MC, Teixeira R, et al (2007). Oral lichen planus and chronic hepatitis C: a controversial association. *Am J Clin Pathol*, **127**, 800-4.
- Denli YG, Durdu M, Karakas M (2004). Diabetes and hepatitis frequency in 140 lichen planus cases in Cukurova region. *J Dermatol*, **31**, 293-8.
- Dormandy TL (1983). An approach to free radicals. *Lancet*, **2**, 1010-4.
- Eisen D, Carrozzo M, Bagan Sebastian JV, et al (2005). Number V Oral lichen planus: clinical features and management. *Oral Dis*, **11**, 338-49.
- Gerayli S, Meshkat Z, Pasdar A, et al (2015). The association between oral lichen planus and hepatitis C virus infection; a report from northeast of iran. *Jundishapur J Microbiol*, **8**, e16741.
- Ghalayani P, Razavi SM, Gholami D (2009). Comparative study of number and distribution of IgG cells in oral lichen planus and oral lichenoid lesions. *Dent Res J (Isfahan)*, **6**, 1-5.
- Ghalyani P, Tavangar A (2010). Evaluation of anxiety and salivary cortisol level in patients with oral lichen planus. *JIDA*, **22**, Pe23-Pe9, En7.
- Gheorghe C, Mihai L, Parlatescu I, et al (2014). Association of oral lichen planus with chronic C hepatitis. Review of the data in literature. *Maedica (Buchar)*, **9**, 98-103.
- Ghods SZ, Daneshpazhooh M, Shahi M, et al (2004). Lichen planus and Hepatitis C: a case-control study. *BMC Dermatol*, **4**, 6.
- Girardi C, Luz C, Cherubini K, et al (2011). Salivary cortisol and dehydroepiandrosterone (DHEA) levels, psychological factors in patients with oral lichen planus. *Arch Oral Biol*,

- 56, 864-8.
- Glick M (2015). *Burket's Oral Medicine*, 12e, Connecticut, People's Medical Publishing House USA.
- Goppelt-Struebe M, Wolter D, Resch K (1989). Glucocorticoids inhibit prostaglandin synthesis not only at the level of phospholipase A2 but also at the level of cyclo-oxygenase/PGE isomerase. *Br J Pharmacol*, **98**, 1287-95.
- Halliwell B (1996). Antioxidants in human health and disease. *Annu Rev Nutr*, **16**, 33-50.
- Halliwell B (2012). Free radicals and antioxidants: updating a personal view. *Nutr Rev*, **70**, 257-65.
- Hirota J, Osaki T, Tatemoto Y (1990). Immunohistochemical staining of infiltrates in oral lichen planus. *Pathol Res Pract*, **186**, 625-32.
- Ishii T (1987). Immunohistochemical demonstration of T cell subsets and accessory cells in oral lichen planus. *J Oral Pathol*, **16**, 356-61.
- Jamalidoust M, Namayandeh M, Asaei S, et al (2014). Determining hepatitis C virus genotype distribution among high-risk groups in Iran using real-time PCR. *World J Gastroenterol*, **20**, 5897-902.
- Jayavelu P, Sambandan T (2012). Prevalence of hepatitis C and hepatitis B virus infection(s) in patients with oral lichen planus. *J Pharm Bioallied Sci*, **4**, 397-405.
- Kaplan I, Ventura-Sharabi Y, Gal G, et al (2012). The dynamics of oral lichen planus: a retrospective clinicopathological study. *Head Neck Pathol*, **6**, 178-83.
- Karavelioglu D, Koytak ES, Bozkaya H, et al (2004). Lichen planus and HCV infection in Turkish patients. *Turk J Gastroenterol*, **15**, 133-6.
- Keller KL, Fenske NA (1998). Uses of vitamins A, C, and E and related compounds in dermatology: a review. *J Am Acad Dermatol*, **39**, 611-25.
- Khan A, Farah CS, Savage NW, et al (2003). Th1 cytokines in oral lichen planus. *J Oral Pathol Med*, **32**, 77-83.
- Krishnaswamy K, Prasad MP, Krishna TP, et al (1995). A case study of nutrient intervention of oral precancerous lesions in India. *Eur J Cancer B Oral Oncol*, **31**, 41-8.
- Kuo RC, Lin HP, Sun A, et al (2013). Prompt healing of erosive oral lichen planus lesion after combined corticosteroid treatment with locally injected triamcinolone acetonide plus oral prednisolone. *J Formos Med Assoc*, **112**, 216-20.
- Lavanya N, Jayanthi P, Rao UK, et al (2011). Oral lichen planus: An update on pathogenesis and treatment. *J Oral Maxillofac Pathol*, **15**, 127-32.
- Leung DY, Bloom JW (2003). Update on glucocorticoid action and resistance. *J Allergy Clin Immunol*, **111**, 3-22; quiz 3.
- Lin HP, Wang YP, Chia JS, et al (2011). Modulation of serum gastric parietal cell antibody level by levamisole and vitamin B12 in oral lichen planus. *Oral Dis*, **17**, 95-101.
- Lodi G, Pellicano R, Carrozzo M (2010). Hepatitis C virus infection and lichen planus: a systematic review with meta-analysis. *Oral Dis*, **16**, 601-12.
- Luis-Montoya P, Cortes-Franco R, Vega-Memije ME (2005). Lichen planus and hepatitis C virus. Is there an association?. *Gac Med Mex*, **141**, 23-5.
- Mahboob A, Haroon TS, Iqbal Z, et al (2003). Frequency of anti-HCV antibodies in patients with lichen planus. *J Coll Physicians Surg Pak*, **13**, 248-51.
- MaziarMojtabavi N, Fatemeh D, Hamid H, et al (2007). Analysis of the related factors in hepatitis C virus infection among hemophilic patients in Isfahan, Iran. *Hepat Mon*, **2007**, 59-62.
- Nagao Y, Sata M (2012). A retrospective case-control study of hepatitis C virus infection and oral lichen planus in Japan: association study with mutations in the core and NSSA region of hepatitis C virus. *BMC Gastroenterol*, **12**, 31.
- Nielsen F, Mikkelsen BB, Nielsen JB, et al (1997). Plasma malondialdehyde as biomarker for oxidative stress: reference interval and effects of life-style factors. *Clin Chem*, **43**, 1209-14.
- Nosratzehi T, Arbabi-Kalati F, Arefpour Z (2015). Lack of association between diabetes mellitus and oral lichen planus in Zahedan (South-East of Iran). *Caspian J Dent Res*, **4**, 8-12.
- Nosratzehi T, Arbabi-Kalati F, Salimi S, et al (2014). The evaluation of psychological factor and salivary cortisol and IgA levels in patients with oral lichen planus. *ZJRMS*, **16**, 31-4.
- Nosratzehi T, Raiesi M, Shahryari B (2016). Lack of relationship between oral lichen planus and hepatitis B and C virus infection: A report from southeast of Iran. *Global J Health Sci*, **9**, 82.
- Oliveira Alves MG, Almeida JD, Balducci I, et al (2010). Oral lichen planus: A retrospective study of 110 Brazilian patients. *BMC Res Notes*, **3**, 157.
- Pakfetrat A, Javadzadeh-Bolouri A, Basir-Shabestari S, et al (2009). Oral Lichen Planus: a retrospective study of 420 Iranian patients. *Med Oral Patol Oral Cir Bucal*, **14**, 315-8.
- Pilli M, Penna A, Zerbini A, et al (2002). Oral lichen planus pathogenesis: A role for the HCV-specific cellular immune response. *Hepatology*, **36**, 1446-52.
- Rabiei M, Sadegh Kanjani M, Kazemnezhad Leili E, et al (2012). The comparison between anxiety, level of salivary cortisol and SIgA in oral lichen planus. *Res Dent Sci*, **9**, 125-31.
- Radwan-Oczko M, Kozłowski Z (2011). Oral lichen planus lesion assessment in relation to general health and oral symptoms. *Adv Clin Exp Med*, **20**, 295-501.
- Rahnama Z, Esfandiarpour I, Farajzadeh S (2005). The relationship between lichen planus and hepatitis C in dermatology outpatients in Kerman, Iran. *Int J Dermatol*, **44**, 746-8.
- Rai B, Kaur J, Jacobs R, et al (2010). Possible action mechanism for curcumin in pre-cancerous lesions based on serum and salivary markers of oxidative stress. *J Oral Sci*, **52**, 251-6.
- Rai B, Kharb S, Jain R, et al (2006). Salivary lipid peroxidation product malonaldehyde in various dental diseases. *World J Med Sci*, **1**, 100-1.
- Rhodus NL, Cheng B, Bowles W, et al (2006). Proinflammatory cytokine levels in saliva before and after treatment of (erosive) oral lichen planus with dexamethasone. *Oral Dis*, **12**, 112-6.
- Romero MA, Seoane J, Varela-Centelles P, et al (2002). Prevalence of diabetes mellitus amongst oral lichen planus patients. Clinical and pathological characteristics. *Med Oral*, **7**, 121-9.
- Roopashree MR, Gondhalekar RV, Shashikanth MC, et al (2010). Pathogenesis of oral lichen planus--a review. *J Oral Pathol Med*, **39**, 729-34.
- Saini R, Al-Maweri SA, Saini D, et al (2010). Oral mucosal lesions in non oral habit diabetic patients and association of diabetes mellitus with oral precancerous lesions. *Diabetes Res Clin Pract*, **89**, 320-6.
- Sato K (1991). Enzyme-linked immunosorbent assay of SIgA in whole saliva of healthy subjects and patients with oral diseases. *Bull Tokyo Med Dent Univ*, **38**, 9-18.
- Seyhan M, Ozcan H, Sahin I, et al (2007). High prevalence of glucose metabolism disturbance in patients with lichen planus. *Diabetes Res Clin Pract*, **77**, 198-202.
- Shen ZY, Liu W, Zhu LK, et al (2012). A retrospective clinicopathological study on oral lichen planus and malignant transformation: analysis of 518 cases. *Med Oral Patol Oral Cir Bucal*, **17**, e943-7.
- Shirzad A, Pouramir M, Seyedmajidi M, et al (2014). Salivary total antioxidant capacity and lipid peroxidation in patients

- with erosive oral lichen planus. *J Dent Res Dent Clin Dent Prospects*, **8**, 35-9.
- Sistig S, Vucicevic-Boras V, Lukac J, et al (2002). Salivary IgA and IgG subclasses in oral mucosal diseases. *Oral Dis*, **8**, 282-6.
- Sugerman PB, Savage NW, Walsh LJ, et al (2002). The pathogenesis of oral lichen planus. *Crit Rev Oral Biol Med*, **13**, 350-65.
- Sun A, Chia JS, Wang JT, et al (2007). Levamisole can reduce the high serum tumour necrosis factor-alpha level to a normal level in patients with erosive oral lichen planus. *Clin Exp Dermatol*, **32**, 308-10.
- Sun A, Wang JT, Chia JS, et al (2005). Serum interleukin-8 level is a more sensitive marker than serum interleukin-6 level in monitoring the disease activity of oral lichen planus. *Br J Dermatol*, **152**, 1187-92.
- Thongprasom K, Chaimusig M, Korkij W, et al (2007). A randomized-controlled trial to compare topical cyclosporin with triamcinolone acetonide for the treatment of oral lichen planus. *J Oral Pathol Med*, **36**, 142-6.
- Torrente-Castells E, Figueiredo R, Berini-Aytes L, et al (2010). Clinical features of oral lichen planus. A retrospective study of 65 cases. *Med Oral Patol Oral Cir Bucal*, **15**, 685-90.
- van der Meij EH, van der Waal I (2003). Lack of clinicopathologic correlation in the diagnosis of oral lichen planus based on the presently available diagnostic criteria and suggestions for modifications. *J Oral Pathol Med*, **32**, 507-12.
- Vincent SD, Fotos PG, Baker KA, et al (1990). Oral lichen planus: the clinical, historical, and therapeutic features of 100 cases. *Oral Surg Oral Med Oral Pathol*, **70**, 165-71.
- Yang LL, Liu XQ, Liu W, et al (2006). Comparative analysis of whole saliva proteomes for the screening of biomarkers for oral lichen planus. *Inflamm Res*, **55**, 405-7.
- Zhao ZZ, Savage NW, Sugerman PB, et al (2002). Mast cell/T cell interactions in oral lichen planus. *J Oral Pathol Med*, **31**, 189-95.



This work is licensed under a Creative Commons Attribution-Non Commercial 4.0 International License.