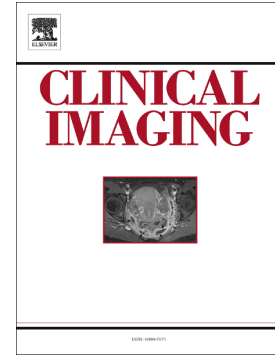

Journal Pre-proof

Asymptomatic novel coronavirus pneumonia patient outside WuHan: the value of CT images in the course of the disease

Chen Lin, Yuxiao Ding, Bin Xie, Zhujian Sun, Xiaogang Li, Zixian Chen, Meng Niu



PII: S0899-7071(20)30056-5

DOI: <https://doi.org/10.1016/j.clinimag.2020.02.008>

Reference: JCT 8843

To appear in: *Clinical Imaging*

Received date: 13 February 2020

Revised date: 17 February 2020

Accepted date: 20 February 2020

Please cite this article as: C. Lin, Y. Ding, B. Xie, et al., Asymptomatic novel coronavirus pneumonia patient outside WuHan: the value of CT images in the course of the disease, *Clinical Imaging*(2020), <https://doi.org/10.1016/j.clinimag.2020.02.008>

This is a PDF file of an article that has undergone enhancements after acceptance, such as the addition of a cover page and metadata, and formatting for readability, but it is not yet the definitive version of record. This version will undergo additional copyediting, typesetting and review before it is published in its final form, but we are providing this version to give early visibility of the article. Please note that, during the production process, errors may be discovered which could affect the content, and all legal disclaimers that apply to the journal pertain.

© 2020 Published by Elsevier.

Clinical Imaging

Asymptomatic Novel Coronavirus Pneumonia patient outside WuHan: The value of CT images in the course of the disease

--Manuscript Draft--

Manuscript Number:	CLM-D-20-00177R1
Article Type:	Case Report
Keywords:	novel coronavirus pneumonia; COVID-19; 2019-nCoV; ground glass opacities; pleural effusion
Corresponding Author:	Chen Lin CHINA
First Author:	Chen Lin
Order of Authors:	Chen Lin Yuxiao Ding Bin Xie Zhujian Sun Xiaogang Li Zixian Chen Meng Niu
Abstract:	The purpose of this case report is to describe the imaging and associated clinical features of an asymptomatic novel coronavirus pneumonia (COVID-19) patient outside WuHan, China. The principle findings are that in this patient with laboratory-confirmed COVID-19, CT findings preceded symptoms and included bilateral pleural effusions, previously not reported in association with COVID-19. The role of this case report is promotion of potential recognition amongst radiologists of this new disease, which has been declared a global health emergency by the World Health Organization (WHO).
Response to Reviewers:	

Full Title Page

Title: Asymptomatic Novel Coronavirus Pneumonia patient outside WuHan: The value of CT images in the course of the disease

Chen Lin^{1,2,3*}, Yuxiao Ding^{1,2}, Bin Xie^{1,2}, Zhujian Sun^{1,2}, Xiaogang Li^{2,4}, Zixian Chen⁵, Meng Niu⁵

1. Department of Radiology, Lanzhou Lung Hospital, Lanzhou, 730000, People's Republic of China .

2. Gansu Provincial Infectious Disease Hospital, Lanzhou, 730000, People's Republic of China .

3. The First Clinical Medical College, Lanzhou University, Lanzhou, 730000, People's Republic of China .

4. Department of Respiratory, Lanzhou Lung Hospital, Lanzhou, 730000, People's Republic of China .

5. Department of Radiology, The First Hospital of Lanzhou University, Lanzhou, 730000, People's Republic of China .

***Corresponding author**

Chen Lin

Department of Radiology, Lanzhou Lung Hospital, No. 968, North Riverside Middle Road, Chengguan District, Lanzhou City, Gansu province, 730000, People's Republic of China.

Email: 1204731562@qq.com, Telephone: 86 18893848858

Grant Support

This work was supported by the Gansu Province Youth Science and Technology Foundation [18JR3RA364]; the Gansu Provincial Health industry research projects Foundation [GSWSKY2016-34]; and the First Hospital of Lanzhou University Hospital Foundation [ldyyyn2015-06].

Asymptomatic Novel Coronavirus Pneumonia patient outside WuHan: The value of CT images in the course of the disease

Abstract

The purpose of this case report is to describe the imaging and associated clinical features of an asymptomatic novel coronavirus pneumonia (COVID-19) patient outside WuHan, China. The principle findings are that in this patient with laboratory-confirmed COVID-19, CT findings preceded symptoms and included bilateral pleural effusions, previously not reported in association with COVID-19. The role of this case report is promotion of potential recognition amongst radiologists of this new disease, which has been declared a global health emergency by the World Health Organization (WHO).

Introduction

In Wuhan, China, in December 2019, a series of pneumonia cases of unknown etiology appeared, soon after diagnosed as being caused by a novel coronavirus initially titled 2019 novel coronavirus (2019-nCoV) and

subsequently officially named COVID-19 by the WHO on February 11, 2020 [1].

As of February 14, 2020, there are 49,053 laboratory-confirmed cases globally [2], 15 of which are in the United States [3]. There is a small but growing body of literature regarding the imaging findings of COVID-19, and the purpose of this case report is to describe the imaging and associated clinical features of an asymptomatic COVID-19 patient outside Wuhan, China, including an imaging finding previously not reported.

Case Report

A 61-year-old asymptomatic man was admitted to our hospital in Lanzhou, China (1,005 miles from WuHan) on January 25, 2020 for close contact with a novel coronavirus pneumonia (NCP) patient more than 10 days prior. The patient was a retired driver in good health, without diabetes, hypertension, cardiovascular disease and had no history of smoking. The patient's temperature and physical examination were normal. Laboratory analysis showed reduced levels of C-reactive protein (1.29 mg/L; normal range, 2–8 mg/L), but white blood cells and lymphocytes were within normal range. The patient's throat swab was positive for NCP nucleic acid.

On the day of admission, high resolution CT (HRCT) showed multiple ground glass opacities (GGOs) in the right lung (Figure 1. A, B). Two days later, CT images revealed an enlarged lesion with small areas of

consolidation in the center (Figure 1. C, D). On the sixth day, CT examination showed that the quantity, range and density of lesions in the right lung had increased further (Figure 1. E). On CT on the 9th day of admission, the lesions progressed further and involved both lungs, with thickened interlobular septa around the lesion in the upper lobe of the right lung (Figure 1. F, G); in addition, there were small bilateral pleural effusions (Figure 1. H).

Since admission, the patient has remained alert and oriented x 3 with only mild shortness of breath after activity on the 11th day of admission (February 4, 2020). He has not had fever, cough, myalgias, fatigue, sputum production, headache, hemoptysis or diarrhea. Notably, he has also remained without complications previously reported in association with COVID-19, including acute respiratory distress syndrome, RNAemia, acute cardiac injury, secondary infection. During the hospitalization, the main treatment has been oral antiviral drugs (Lopinavir and Ritonavir tablets), interferon and methylprednisolone. On the 23th day of admission (February 16, 2020), CT showed that the patient's pleural effusions had resolved and bilateral pulmonary lesions improved (Figure 2. A, B), however the patient remains hospitalized because his nucleic acid test is still positive.

Discussion

The purpose of this case report is to describe the imaging and associated clinical features of an asymptomatic COVID-19 patient outside WuHan, China. The principle findings are that in this patient with laboratory-confirmed COVID-19, CT findings preceded symptoms and included bilateral pleural effusions, previously not reported in association with COVID-19.

There is a small but growing body of literature regarding the imaging findings of COVID-19 (11 articles in the English language literature in Pub Med on February 15, 2020 [4]), and the patient in this case report demonstrates both similarities and differences compared with the literature. Most noteworthy is that the COVID-19 patient in this case is the first reported, to the best of our knowledge, with associated bilateral pleural effusions. On the other hand, consistent with 98% of patients in the initial landmark Lancet article with a sample size of 41 [5], the imaging findings of this patient with laboratory-confirmed COVID-19 infection ultimately had bilateral pulmonary involvement. Yet in contrast to patients in the Lancet cohort for whom “Later chest CT images showed bilateral ground-glass opacity, whereas the consolidation had been resolved” [5], for the patient in this case report, earlier chest CT images showed ground glass opacities (GGOs) and later chest CT images showed progressive bilateral consolidation.

The COVID-19 patient in this report was also similar to a study from European Radiology with a sample size of 63 which demonstrated

multilobar findings, GGOs and progression in the majority of patients [6].

The COVID-19 patient in this report showed similarity to a cohort of 21 patients reported in

Radiology as well, in which the lung abnormalities on chest CT in patients with COVID-19 showed greatest severity approximately 10 days after initial onset of symptoms [7]; in the patient in this case report, CT chest changes were greatest at day nine. In sum, emerging information seems to suggest that typical imaging findings of COVID-19 include GGO and/or mixed GGO and mixed consolidation [8]. This case report contributes to the growing literature on COVID-19 by reporting for the first time the associated finding of bilateral pleural effusions.

Limitations of this case report include the sample size (n=1) and lack of some desired information, including sputum culture or analysis of pleural fluid. Despite these limitations, the goal in writing this case report is hopefully the education of radiologists and other clinicians of the recognition of this new disease [9] which has been declared a global health emergency by the WHO.

In conclusion, this patient with laboratory-confirmed COVID-19 infection demonstrates that abnormal CT findings can precede clinical symptoms and that these abnormal CT findings may include bilateral pleural effusions. Future series and studies should seek to assess if this is the case on a larger scale, as well as the association between viral

clearance of COVID-19 on laboratory analysis and clearance on imaging. In patients whose exposure history and epidemiological history can be determined, the imaging manifestations, high resolution CT may be helpful for the diagnosis and observation in the course of this unfortunately exponentially growing disease.

Author's note: The authors wish to thank Elizabeth K. Arleo MD for her assistance in writing this article.

Editor's note: *Clinical Imaging* extends its best wishes to the radiologists and other health care providers in China, as well as to the patients affected with COVID-19 – our thoughts are with you during this unbelievably difficult time.

Highlights:

- Patient(s) with laboratory-confirmed COVID-19 infection can be asymptomatic and yet demonstrate abnormal CT findings which precede clinical symptoms.
- COVID-19 can be associated with small bilateral pleural effusions.

References

1. Center for Disease Control and Prevention (CDC). Locations with confirmed COVID-19 Cases.
<https://www.cdc.gov/coronavirus/2019-ncov/locations-confirmed-cases.html>. Accessed February 15, 2020.
2. Center for Disease Control and Prevention (CDC). Coronavirus disease 2019 (COVID-19) Situation Report-25.
https://www.who.int/docs/default-source/coronaviruse/situation-reports/20200214-sitrep-25-covid-19.pdf?sfvrsn=61dda7d_2.
Accessed February 15, 2020.
3. Center for Disease Control and Prevention (CDC). Coronavirus Disease 2019 (COVID-19) in the U.S.
<https://www.cdc.gov/coronavirus/2019-ncov/cases-in-us.html> .
Accessed February 15,
4. PubMed search on novel coronavirus pneumonia AND radiology,
February 15, 2020:
<https://www.ncbi.nlm.nih.gov/pubmed/?term=novel+coronavirus+pneumonia+AND+radiology>).
5. Huang C, Wang Y, Li X et al. Clinical features of patients infected with 2019 novel coronavirus in Wuhan, China. Lancet. 2020 Jan 24.

pii: S0140-6736(20)30183-5. doi: 10.1016/S0140-6736(20)30183-5.

[Epub ahead of print]

6. Pan Y, Guan H, Zhou S, et al. Initial CT findings and temporal changes in patients with the novel coronavirus pneumonia (2019-nCoV): a study of 63 patients in Wuhan, China. *Eur Radiol.* 2020 Feb 13. doi: 10.1007/s00330-020-06731-x.
7. Pan F, Ye T, Sun P et al. Time Course of Lung Changes On Chest CT During Recovery From 2019 Novel Coronavirus(COVID-19) Pneumonia. *Radiology.* 2020 Feb 13:200370. doi: 10.1148/radiol.2020200370. [Epub ahead of print]
8. Xie X, Zhong Z, Zhao W, et al. Chest CT for Typical 2019-nCoV Pneumonia: Relationship to Negative RT-PCR Testing. *Radiology.* 2020 Feb 12:200343. doi: 10.1148/radiol.2020200343. [Epub ahead of print]
9. Vandembroucke J. In Defense of Case Reports and Case Series. *Ann Intern Med.* 2001;134:330-334.

Figure Legend

Figure 1

Unenhanced CT images: **A, B**, Images shows ground glass opacities in right lung. **C, D**, Images obtained 2 days later shows progressive ground-glass opacities with small areas of consolidation in the center. **E**, On the sixth day, images show the quantity, range and density of lesions in the right lung increased further. **F, G, H**, Images obtained on the 9th day demonstrate that lesions progressed further and involved both lungs, with thickened interlobular septa around the lesion in the upper lobe of the right lung, and the appearance of small bilateral pleural effusions.

Figure 2

Unenhanced CT images from the 23rd day of admission demonstrate: **A, B**, Resolution of bilateral pleural effusions and improvement of bilateral pulmonary lesions.

Figure 1

[Click here to access/download;Figure;Figure1.tif](#)

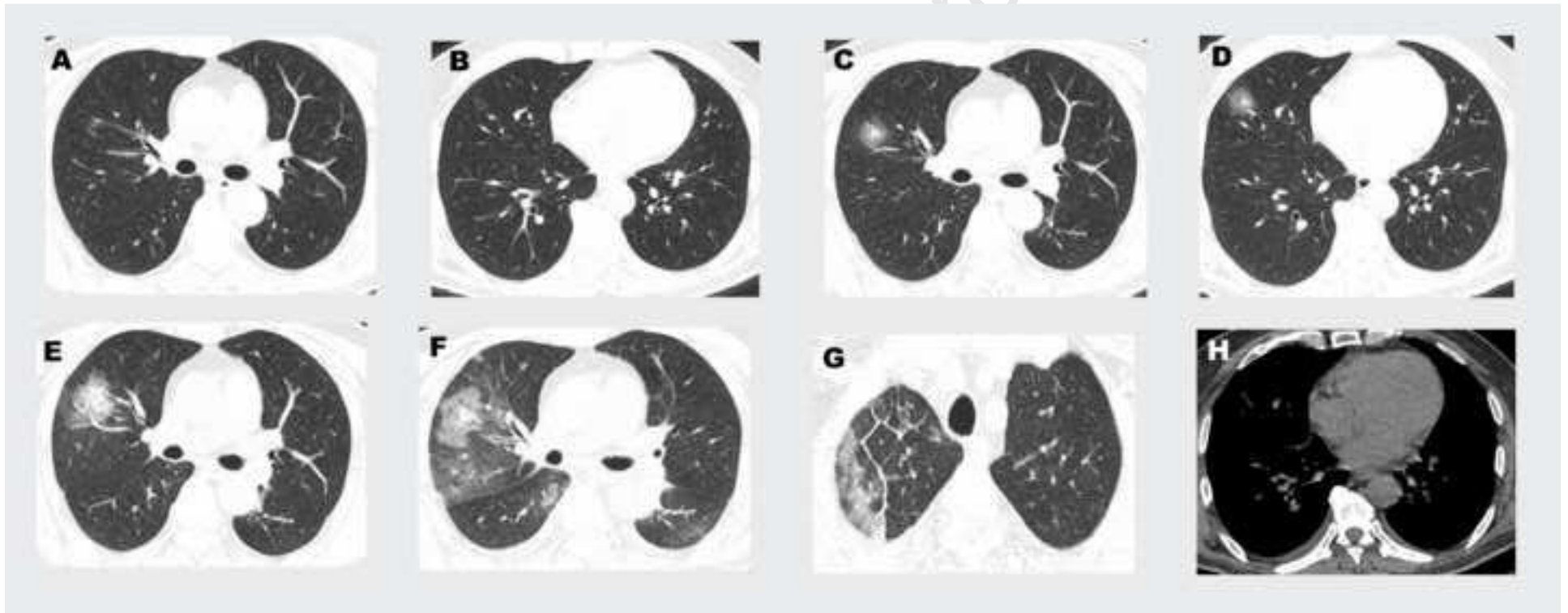
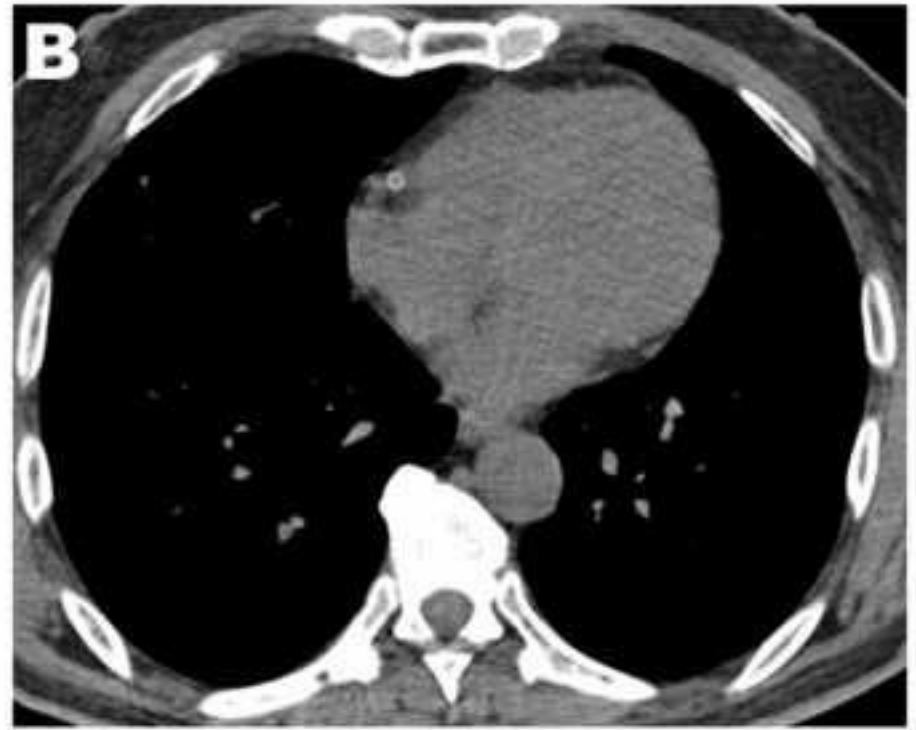
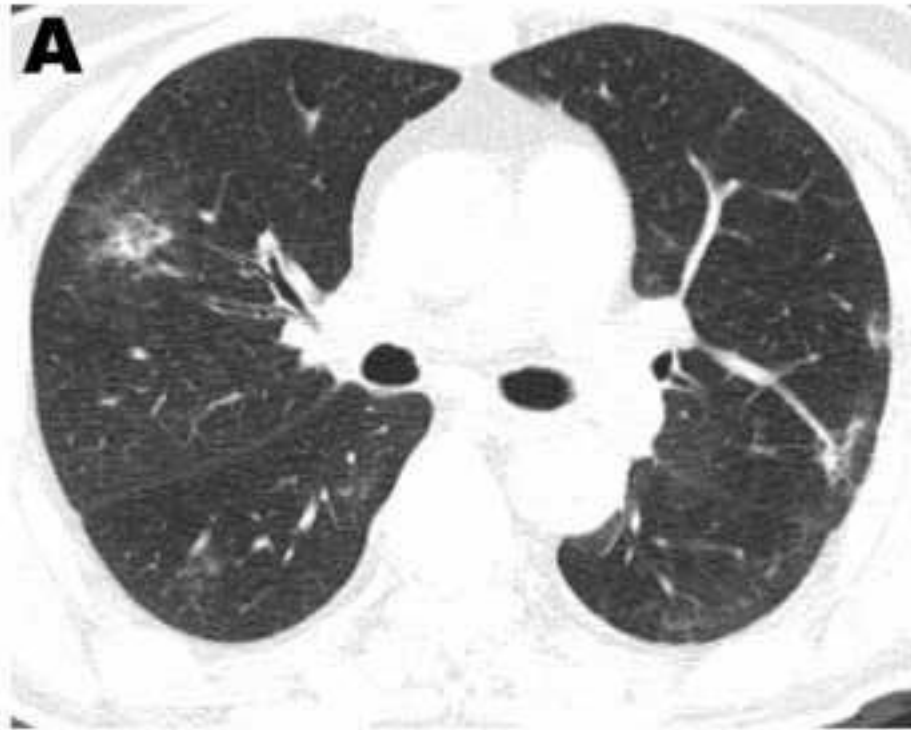
Figure2

[Click here to access/download;Figure;Figure2.tif](#)



Jou.

Highlights:

- Patient(s) with laboratory-confirmed COVID-19 infection can be asymptomatic and yet demonstrate abnormal CT findings which precede clinical symptoms.
- COVID-19 can be associated with small bilateral pleural effusions.

Journal Pre-proof