



Does synchronous early head and neck cancer with esophageal cancer need treatment after preoperative chemotherapy?

Kohei Kanamori^{1,2} · Daisuke Kurita¹ · Yuki Hirano¹ · Koshiro Ishiyama¹ · Junya Oguma¹ · Kenkichi Masutomi^{2,3} · Hiroyuki Daiko¹

Received: 1 September 2021 / Accepted: 11 November 2021 / Published online: 27 November 2021
© The Japanese Association for Thoracic Surgery 2021

Abstract

Objective Treatment options for patients with resectable thoracic esophageal squamous cell cancer (ESCC) and synchronous head and neck cancer (HNC) are unclear. Little has been reported about the effects of chemotherapy on early HNC. The aim of this study was to investigate the treatment outcomes of resectable thoracic ESCC with synchronous early HNC.

Methods We retrospectively reviewed 37 patients undergoing esophagectomy for thoracic ESCC with synchronous early HNC from January 2008 to December 2018.

Results Among 37 patients who had synchronous early HNC, 27 patients received preoperative therapy for ESCC before HNC treatment, and 16 of 27 patients achieved a complete response for HNC by preoperative chemotherapy. Fifteen of 16 patients did not receive additional treatment, and regional recurrence of HNC was not observed. In one other case, an oral excision was performed, but no cancer cell remnants were found pathologically. No significant difference in overall survival and disease-free survival was observed between 15 patients with follow-up and 22 patients with surgery or radiation.

Conclusion Our results indicate that early HNC with comorbid ESCC could be followed up without additional treatment if preoperative chemotherapy is successful.

Keywords Esophageal cancer · Head and neck cancer · Synchronous multiple primary neoplasms · Neoadjuvant therapy

Introduction

Esophageal squamous cell cancer (ESCC) is frequently associated with head and neck cancer (HNC), and the incidence was reported at approximately 2% [1]. Particularly in East Asia, including Japan, many people (11–40%) have inactive ALDH2 enzyme [2, 3], and thus the incidence of ESCC and HNC, which are greatly affected by alcohol consumption, is relatively high [4]. The adjusted sequence ratio per 100,000 esophageal cancer and HNC cases is 12.9 and 19.8

in Japanese males [5] and 7.9 and 19.5 in American males [6, 7], respectively.

Endoscopic treatment for ESCC T1aN0M0 or surgical monotherapy for ESCC T1bN0M0 is the standard of care. The standard treatment for patients with ESCC T2 or deeper or N positivity is preoperative chemotherapy followed by surgery according to Japanese guidelines [8], and that is preoperative chemoradiotherapy followed by surgery according to the National Comprehensive Cancer Network guidelines [9]. The standard of care for early HNC is resection or radiotherapy in both guidelines [10, 11]. Treatment options for patients with resectable thoracic ESCC and synchronous HNC are uncertain and are not defined in any guidelines. Of note, little has been reported about the treatment of ESCC with synchronous early HNC. Comorbid ESCC may lead to chemotherapy for early HNC, which is not standard therapy, but the results have not been reported. We aimed to retrospectively analyze the treatment outcomes of resectable thoracic ESCC with synchronous early HNC at a single center.

✉ Hiroyuki Daiko
hdaiko@ncc.go.jp

¹ Department of Esophageal Surgery, National Cancer Center Hospital, 5-5-1 Tsukiji, Chuo-ku, Tokyo 104-0045, Japan

² Course of Advanced Clinical Research of Cancer, Juntendo University Graduate School of Medicine, 2-1-1 Hongo, Bunkyo-ku 113-8421, Japan

³ Division of Cancer Stem Cell, National Cancer Research Institute, 5-5-1 Tsukiji, Chuo-ku, Tokyo 104-0045, Japan

Materials and methods

We collected the data of 1061 patients undergoing esophagectomy for ESCC from January 2008 to December 2018 at the National Cancer Center Hospital. Among them, we excluded cervical or abdominal ESCC and cases of incomplete resection for ESCC and reviewed 37 patients who underwent esophagectomy for thoracic ESCC with synchronous HNC Stage I or II. We extracted demographics, medical history, diagnosis, treatment, and prognosis data from electronic medical records. All patients received computed tomography and upper gastrointestinal endoscopy with biopsy at our hospital. The pathologist made a histological diagnosis, and staging was undertaken in a conference with esophageal surgeon, head and neck surgeons, endoscopists, and radiologists. In this study, untreated HNCs that were identified before treatment for ESCC were defined as synchronous HNCs. ESCC and HNC were staged according to the UICC 7th edition [12]. Stage I and stage II HNCs were defined as early cancers.

Survival analysis was calculated using the Kaplan–Meier method. The statistical examination was performed using SPSS 26.0 (IBM SPSS, New York, USA), and *P*-values of less than 0.05 were considered to indicate statistical significance.

Results

Patients' characteristics are shown in Table 1. Figure 1 shows the treatment methods for early HNC. Twenty-seven patients received chemotherapy given for the purpose of treating ESCC before radical treatment for HNC. Preoperative treatment for ESCC included cisplatin and 5-FU (CF), docetaxel, cisplatin and 5-FU (DCF), or chemoradiotherapy (CRT). Preoperative CF consisted of cisplatin 80 mg/m² on day 1 and 5-FU 800 mg/m² continuous infusion over days 1–5, up to 2 courses with a 3-week interval. Preoperative DCF consisted of 70 mg/m² docetaxel on day 1, 70 mg/m² cisplatin on day 1750 mg/m² 5-FU continuous infusion over days 1–5, up to 3 courses with a 3-week interval. Preoperative CRT consisted of chemoradiation (41.4 Gy/23 fractions) with 2 courses of CF (75 mg/m² cisplatin on day 1 and 5-FU 1000 mg/m² continuous infusion over days 1–4) repeated every 4 weeks.

All 37 cases with early HNC underwent esophagectomy, gastric tube reconstruction, and cervical anastomosis for ESCC, and R0 resection for ESCC was achieved in all cases. In 27 patients who received preoperative therapy for ESCC before HNC treatment, resection or radiotherapy was performed in consideration of the therapeutic effect

Table 1 Characteristics of 37 patients who had synchronous esophageal cancer and early head and neck cancer

	<i>n</i> = 37
Sex, male/female	36/1
Age, years, median (range)	65 (49–78)
<i>Site of ESCC</i>	
Ut	9
Mt	14
Lt	14
<i>Site of HNC</i>	
Hypopharynx	29
Oropharynx	5
Larynx	2
Intraoral	1
<i>Clinical stage of ESCC</i>	
I	7
II	9
III	19
IV	2
<i>Clinical stage of HNC</i>	
I	26
II	11
III	0
IV	0
<i>Preoperative therapy for ESCC</i>	
None	8
CF therapy	17
DCF therapy	7
Chemoradiotherapy	5

ESCC esophageal squamous cell cancer, *HNC* head and neck cancer, *CF* cisplatin plus 5-FU, *DCF* docetaxel, cisplatin plus 5-FU

on HNCs. Among them, 16 patients achieve a complete response (CR) of HNC by preoperative chemotherapy for ESCC, and 15 patients did not receive additional treatment. In one other case, an oral excision was performed, but no cancer cell remnants were found pathologically. The effect of treatment is mainly diagnosed by endoscopic findings and does not necessarily require pathological examination.

Among the early HNC patients, those with residual cancer after preoperative chemotherapy and those who did not receive preoperative chemotherapy were treated with surgery or radiation therapy. Of the 13 patients who underwent surgery, five underwent external incision, three at the same time as esophagectomy and two before esophagectomy; three underwent transoral video-laryngoscopic surgery (TOVS), one before and two after esophagectomy; five underwent endoscopic submucosal dissection (ESD), all before esophagectomy. Eight patients underwent radiation therapy, all after esophagectomy. The decision to intervene

Fig. 1 Overview of the steps involved in treatment of synchronous early HNC. *HNC* head and neck cancer, *ESCC* esophageal squamous cell cancer, *CR* complete response, *PR* partial response, *CRT* chemoradiotherapy

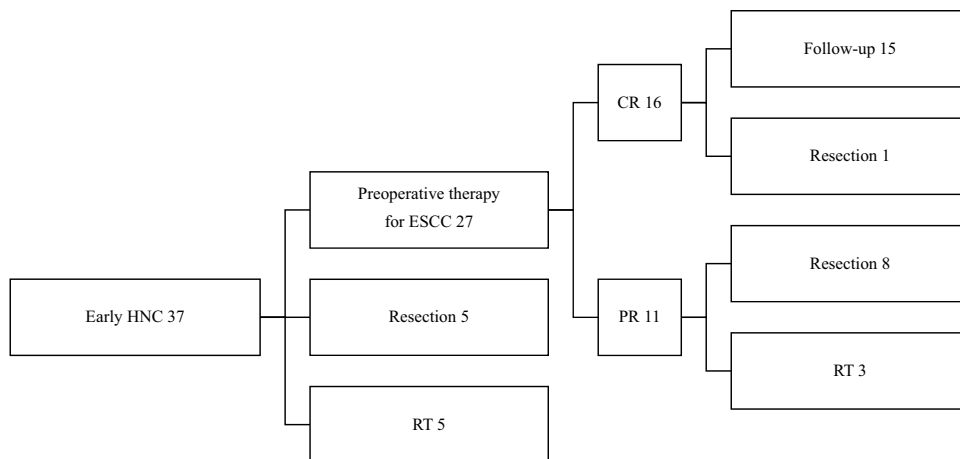


Table 2 The number of recurrences of ESCC and HNC

	All cases (n=37)	Follow-up (n=15)	Intervention (n=22)	p
Local (ESCC)	7	4	3	0.28
Local (HNC)	2	0	2	0.34
Distant metastatic (ESCC)	1	1	0	0.41
Distant metastatic (HNC)	0	0	0	N.A

ESCC esophageal squamous cell cancer, *HNC* head and neck cancer, *N.A.* not assessed

was made by the attending otolaryngologist. As a result, 15 patients were treated with chemotherapy alone for HNC and followed up, and 22 patients were treated with surgery or radiotherapy for HNC.

The prognosis was compared in two groups: “Follow-up Group”, in which chemotherapy resulted in CR for

HNC and no additional treatment for HNC was given, and “Intervention Group”, in which radical treatment other than chemotherapy for HNC was given. The number of recurrences of ESCC and HNC in each group is shown in Table 2. In Follow-up Group, there was no case of HNC recurrence. Local recurrence was observed in 9 patients, and distant metastatic recurrence was observed in one patient. Among them, four patients underwent resection for recurrence, and six patients received nonsurgical treatment. Overall survival (OS) and disease-free survival (DFS) were compared between the two groups (Fig. 2). No significant difference was observed between the two groups. Figure 3 shows a survival curve stratified by Stage I/II and Stage III/IV of ESCC. Regardless of the progression of ESCC, the prognosis was not poor for patients who did not receive additional treatment for HNC that achieved CR.

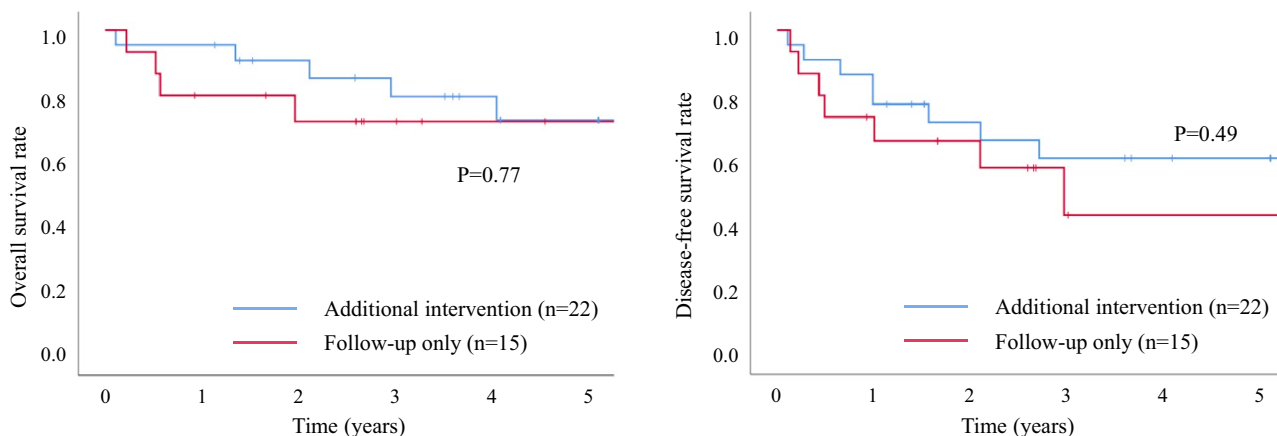
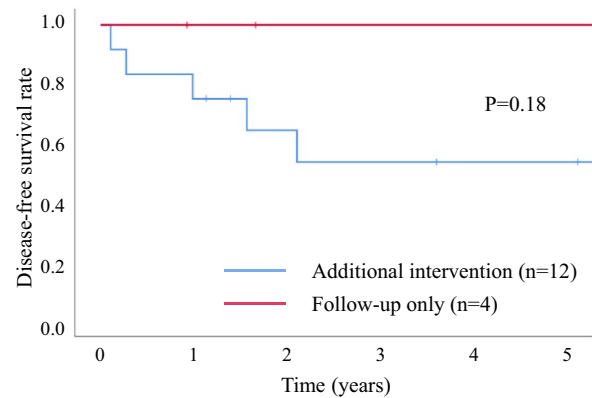
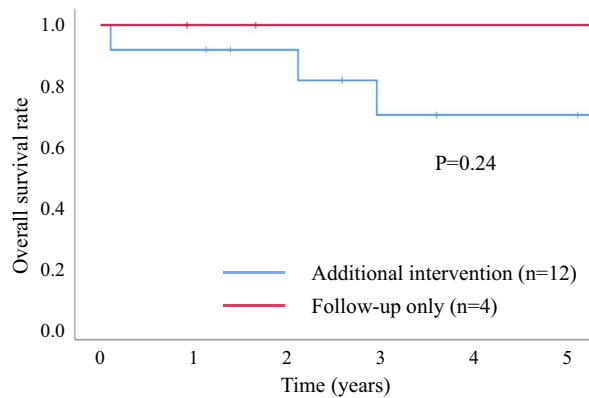


Fig. 2 Comparison of OS and DFS between patients who underwent follow-up and patients who underwent intervention for early HNC. No significant difference was observed. *HNC* head and neck cancer, *OS* overall survival, *DFS* disease-free survival

ESCC Stage I/II



ESCC Stage III/IV

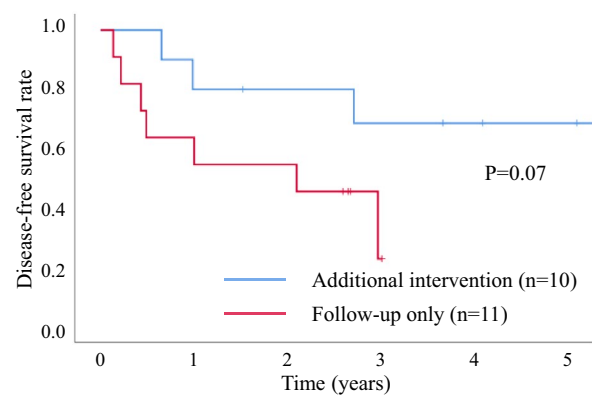
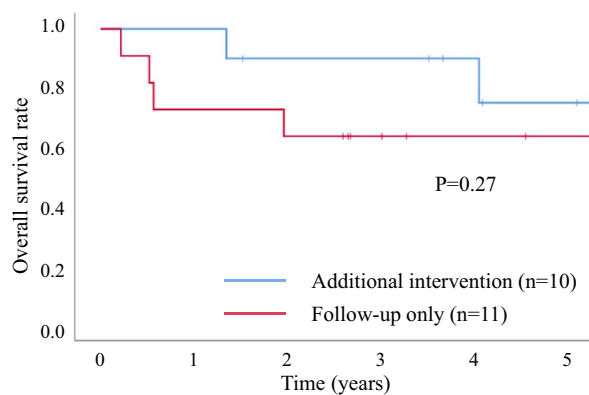


Fig. 3 Comparison of OS and DFS between patients who received follow-up and those who received intervention for early HNC stratified by ESCC progression. No significant difference was observed.

HNC head and neck cancer, OS overall survival, DFS disease-free survival, ESCC esophageal squamous cell cancer

Discussion

It is widely known that ESCC is often associated with HNC [1], and screening tests for HNC are often performed before esophagectomy for ESCC. Advances in endoscopic technologies such as narrow band imaging (NBI) have enabled the early detection of HNC [13], and the likelihood of identifying synchronous early HNC before esophagectomy is increasing. Early HNC is thought to require resection or radiotherapy in the Japanese guidelines [10]. Both ESCC and HNC are squamous cell carcinomas, and platinum or taxanes are commonly recommended for advanced disease as chemotherapy in the respective guidelines [8, 10].

In general, single chemotherapy aimed at the radical cure of solid tumors is not standard. There are reports of a small number of cases in which chemotherapy alone was attempted to treat HNC. It has been reported that for squamous cell carcinoma of the larynx and pharynx of any stage with CR after induction chemotherapy, 54.9% of patients could be controlled by continuing chemotherapy [14]. In

addition, 10 out of 11 patients who received induction chemotherapy (paclitaxel, ifosfamide, and cisplatin) for stage II to IV laryngeal cancer and achieved CR were reported to be recurrence-free without additional treatment [15]. However, with regards to early HNC, the effects of chemotherapy are not known. We revealed new findings of early HNC associated with ESCC in this study. Relatively intense chemotherapy was administered to early HNC, and the effect of chemotherapy for early HNC was CR in 16/27 (59.3%), and partial response (PR) in 11/27 (40.7%), while none of the cases showed progression. Notably, in patients with CR, the prognosis was favorable, with none of the HNC recurrent without additional treatment.

Few reports have been published on the treatment of HNC associated with esophageal cancer distinguishing between early-stage and advanced cancers, but there are no reports describing the effect of chemotherapy alone on early HNC. Okamoto et al. [16] reported nine cases of early HNC associated with advanced ESCC, and all cases underwent either chemoradiotherapy or endoscopic resection. Our results

suggest that a treatment strategy that gives priority to ESCC over early HNC may be acceptable.

The limitations of this study are the small sample size at a single-center and the retrospective data collection.

Conclusions

Our results indicate that early HNC with comorbid ESCC could be followed up without additional treatment if preoperative chemotherapy is successful.

Declarations

Conflict of interest All authors declare that they have no conflict of interest.

References

- Lee GD, Kim YH, Kim JB, Choi SH, Kim HR, Kim DK, et al. Esophageal cancer associated with multiple primary cancers: surgical approaches and long-term survival. *Ann Surg Oncol*. 2013;20:4260–6.
- Tanaka F, Yamamoto K, Suzuki S, Inoue H, Tsurumaru M, Kajiyama Y, et al. Strong interaction between the effects of alcohol consumption and smoking on oesophageal squamous cell carcinoma among individuals with ADH1B and/or ALDH2 risk alleles. *Gut*. 2010;59:1457–64.
- Li H, Borinskaya S, Yoshimura K, Kal'ina N, Marusin A, Stepanov VA, et al. Refined geographic distribution of the oriental ALDH2*504Lys (nee 487Lys) variant. *Ann Hum Genet*. 2009;73:335–45.
- Lu Y, Sobue T, Kitamura T, Matsuse R, Kitamura Y, Matsuo K, et al. Cigarette smoking, alcohol drinking, and oral cavity and pharyngeal cancer in the Japanese: a population-based cohort study in Japan. *Eur J Cancer Prev*. 2018;27:171–9.
- Cancer Registry and Statistics. Cancer Information Service, National Cancer Center, Japan (Monitoring of Cancer Incidence in Japan (MCIJ)) [https://ganjoho.jp/data/reg_stat/statistics/dl/cancer_incidence\(1975-2015\).xls](https://ganjoho.jp/data/reg_stat/statistics/dl/cancer_incidence(1975-2015).xls) Accessed 30 Mar 2020.
- Esophagus. The Cancer Statistics Center website, American Cancer Society. https://cancerstatisticscenter.cancer.org/?_ga=2.20041023.660573594.1584808708-2063177524.1580710906#!/cancer-site/Esophagus Accessed 30 Mar 2020.
- Oral cavity and Pharynx. The Cancer Statistics Center website, American Cancer Society. https://cancerstatisticscenter.cancer.org/?_ga=2.20041023.660573594.1584808708-2063177524.1580710906#!/cancer-site/Oral%20cavity%20and%20pharynx Accessed 30 Mar 2020.
- The JAPAN Esophageal Society. Guidelines for Diagnosis and Treatment of Carcinoma of the Esophagus. Tokyo: KANEHARA & CO., LTD.; 2017.
- NCCN Clinical Practice Guidelines in Oncology. Esophageal and Esophagogastric Junction Cancers. Version 1.2020. https://www.nccn.org/professionals/physician_gls/pdf/esophageal.pdf Accessed 26 Mar 2020.
- Japan Society for Head and Neck Cancer. Japanese clinical practice guidelines for Head and Neck Cancer. Tokyo: KANEHARA & CO., LTD.; 2018.
- NCCN clinical practice Guidelines in Oncology. Head and Neck Cancers. Version 1.2020. https://www.nccn.org/professionals/physician_gls/pdf/head-and-neck.pdf Accessed 26 Mar 2020.
- Leslie HS, Mary KG, Christian W. TNM Classification of Malignant Tumours. 7th ed. New Jersey: Wiley-Blackwell; 2011.
- Zhou H, Zhang J, Guo L, Nie J, Zhu C, Ma X. The value of narrow band imaging in diagnosis of head and neck cancer: a meta-analysis. *Sci Rep*. 2018;8:515.
- Holsinger FC, Lin HY, Bassot V, Laccourreye O. Platin-based exclusive chemotherapy for selected patients with squamous cell carcinoma of the larynx and pharynx. *Cancer*. 2009;115:3909–18.
- Holsinger FC, Kies MS, Diaz EM Jr, Gillenwater AM, Lewin JS, Ginsberg LE, et al. Durable long-term remission with chemotherapy alone for stage II to IV laryngeal cancer. *J Clin Oncol*. 2009;27:1976–82.
- Okamoto T, Katada C, Komori S, Yamashita K, Miyamoto S, Kano K, et al. A retrospective study of treatment for curative synchronous double primary cancers of the head and neck and the esophagus. *Auris Nasus Larynx*. 2018;45:1053–60.

Publisher's Note Springer Nature remains neutral with regard to jurisdictional claims in published maps and institutional affiliations.